Journal of Advanced Biomedical Sciences
https://jabs.fums.ac.ir/
Online ISSN: 2783-1523
Fasa University of Medical Sciences

Downloaded from jabs.fums.ac.ir at 7:16 +0330 on Sunday November 29th 2026

Comparative Evaluation of Topical *Camellia sinensis* and *Daphne mucronata* Versus Silver Sulfadiazine on Cutaneous Wound Healing in Rats: Modulation of TNF-α, Oxidative Stress, and Collagen Remodeling

Sajjad Johari[1], Leila Derakhshan[1], Seyedeh Ommolbanin Ghasemian[2], Forough Kajbaf[1]

1. Department of Veterinary Medicine, Sho.C., Islamic Azad University, Shoushtar,
2. Department of Veterinary Medicine, Be.C., Islamic Azad University, Behbahan, Iran

Article Info

Article Type:
Original Article

Article history:
Received
28 Jul 2026
Received in revised form
04 Aug 2026
Accepted
08 Sep 2026
Published online
10 Sep 2026

Publisher
Fasa University of Medical Sciences

Abstract

Background & Objective: Cutaneous wound healing remains a clinical challenge, and herbal extracts may provide therapeutic options for enhancing tissue repair. This study evaluated the topical effects of *Camellia sinensis*, *Daphne mucronata*, and their combination on wound healing in rats.

Material & Methods: Forty male Wistar rats with full-thickness excisional skin wounds were randomly allocated to five groups (n = 8): a negative control group, a group treated with 1% silver sulfadiazine, and three groups treated with 5% hydroethanolic ointments containing *C. sinensis*, *D. mucronata*, or their combination. Wound healing was assessed on days 3, 7, 14, and 21 using macroscopic and histomorphometric parameters, including wound closure, re-epithelialization, angiogenesis, fibroblast activity, collagen deposition, and inflammatory cell infiltration. On day 21, tissue concentrations of tumor necrosis factor-alpha (TNF-α) and malondialdehyde (MDA), as well as superoxide dismutase (SOD) activity, were measured. Longitudinal outcomes were analyzed using repeated-measures two-way analysis of variance.

Results: All herbal treatments significantly improved wound-healing indices compared with the negative control ($P < 0.001$). *C. sinensis* produced the highest wound-healing percentage on day 21 (97.50 ± 0.11%) and reduced MDA and TNF-α concentrations by 60.49% and 58.02%, respectively, while increasing SOD activity by 157.89%. The combined treatment reduced inflammatory cell infiltration and improved collagen organization.

Conclusion: Topical application of *C. sinensis*, *D. mucronata*, and their combination improved macroscopic, histomorphometric, and biochemical indicators of wound healing. *C. sinensis* demonstrated particularly pronounced effects on late-stage wound closure and oxidative and inflammatory responses.

Keywords: Wound healing, Camellia sinensis, Daphne mucronata, Antioxidants, Cytokines

Cite this article: Johari S, Derakhshan L, Ghasemian S.O, Kajbaf F. Comparative Evaluation of Topical *Camellia sinensis* and *Daphne mucronata* Versus Silver Sulfadiazine on Cutaneous Wound Healing in Rats: Modulation of TNF-α, Oxidative Stress, and Collagen Remodeling. J Adv Biomed Sci. 2026; 16(4): 348-369.
DOI: 10.18502/jabs.v16i4.22277

Introduction

Cutaneous wound healing is not merely a mechanical breach in the body's protective barrier; it initiates a complex and interconnected sequence of events involving inflammation, oxidative stress, extracellular matrix remodeling, and angiogenesis. Any disruption of this regulatory network can derail the repair process, resulting in persistent inflammation, delayed wound closure, secondary infection,

Corresponding Author: Seyedeh Ommolbanin Ghasemian, Department of Veterinary Medicine, Be.C., Islamic Azad University, Behbahan, Iran.
Email: Ommolbanin.Ghasemian@iau.ac.ir

CC BY NC

[DOI: 10.18502/jabs.v16i4.22277]
Downloaded from jabs.fums.ac.ir at 7:16 +0330 on Sunday November 29th 2026

and unfavorable scar formation. Wound repair is a dynamic, multistage process that classically comprises hemostasis, inflammation, cell proliferation, and tissue remodeling. Successful progression through these stages depends on the spatiotemporal coordination of platelets, neutrophils, macrophages, fibroblasts, keratinocytes, endothelial cells, and extracellular matrix components (1,2). From the perspective of veterinary science and comparative medicine, delayed wound repair increases pain, raises the risk of microbial contamination, prolongs treatment duration, increases the costs of care, and reduces quality of life. These clinical and practical consequences underscore the importance of interventions capable of targeting several major aspects of the repair process simultaneously.

The inflammatory phase is essential for removing damaged tissue and initiating regeneration. However, excessive or prolonged inflammatory activity may damage surrounding healthy tissue and impair subsequent stages of repair. Macrophages serve as central regulators of this phase and, through mediators such as tumor necrosis factor-alpha (TNF-α), participate in immune cell recruitment, fibroblast regulation, extracellular matrix restoration, and the transition from inflammation to proliferation (3,4). Elevated TNF-α levels may intensify inflammatory cell infiltration, amplify reactive oxygen species production, aggravate cellular injury, and disrupt collagen synthesis and organization. Accordingly, modulating TNF-α production without compromising host defense represents an important objective of pharmacological and herbal interventions in wound management.

Oxidative stress is another major determinant of wound healing outcomes. Physiological levels of reactive oxygen species support cell signaling, antimicrobial defense, and the initiation of angiogenesis, whereas excessive accumulation of these molecules promotes lipid peroxidation, protein injury, nucleic acid damage, and impaired survival of keratinocytes and fibroblasts (5,6). Malondialdehyde (MDA) is commonly used as a marker of lipid peroxidation and reflects the extent of oxidative membrane injury in tissue samples as assessed using the thiobarbituric acid assay (7). Superoxide dismutase (SOD) is a major component of the endogenous antioxidant defense system that catalyzes the conversion of superoxide radicals into hydrogen peroxide, thereby limiting the propagation of oxidative chain reactions. A reduction in MDA levels, together with preserved or increased SOD activity, suggests an improved oxidant-antioxidant balance within the wound microenvironment. The interpretive value of these biomarkers is enhanced when they are assessed alongside inflammatory and histopathological findings.

Conventional topical management of burn wounds and other cutaneous injuries commonly aims to control infection, maintain moisture, and accelerate re-epithelialization. Silver sulfadiazine is a widely used agent in topical burn management and, owing to its broad antimicrobial activity, has served as a standard treatment or positive control in many animal studies (8). Nevertheless, antimicrobial efficacy alone is insufficient to address the multiple processes involved in tissue repair. Optimal healing requires coordinated regulation of inflammation, attenuation of oxidative injury, preservation of fibroblast function, stimulation of collagen synthesis and maturation, acceleration of re-epithelialization, and proper granulation tissue formation. These considerations have prompted increasing interest in multitarget natural products, particularly plant extracts rich in polyphenols and flavonoids (9-12).

Green tea, derived from *Camellia sinensis*, is a medicinal plant rich in catechins, especially epigallocatechin-3-gallate, and its antioxidant, anti-inflammatory, and cell-modulatory properties have been extensively

[DOI: 10.18502/jabs.v16i4.22277]
Downloaded from jabs.fums.ac.ir at 7:16 +0330 on Sunday November 29th 2026

investigated (13,14). Tea polyphenols can promote progression of the wound-healing process toward the proliferative and remodeling phases by scavenging reactive oxygen species, strengthening endogenous antioxidant systems, and modulating cytokine signaling pathways. Experimental evidence indicates that *C. sinensis* extract improves wound closure, re-epithelialization, granulation tissue formation, and collagen organization in animal models (15,16). In addition, white tea extract, which is also derived from *C. sinensis*, has demonstrated beneficial effects on indices of cutaneous wound repair in rats (17). Iranian studies have also reported favorable effects of alcoholic green tea extract on surgical and burn wound healing in rats (18).

Alongside green tea, species of the genus *Daphne* contain a diverse range of bioactive compounds, including flavonoids, coumarins, lignans, and phenolic constituents, and have considerable potential for modulating inflammation, reducing oxidative stress, and promoting tissue regeneration. The wound-healing efficacy of *Daphne oleoides* subsp. *kurdica* has been reported in experimental wound models, and active constituents have been identified through bioassay-guided isolation (19). In addition, a hydroalcoholic extract of *Daphne mucronata* incorporated into an alginate dermal scaffold improved full-thickness wound repair, enhanced skin regeneration, and improved histological wound-healing features (20). These findings indicate that *D. mucronata* merits attention both as a traditional topical agent and as a source of active compounds that may influence multiple stages of wound healing.

Despite these promising findings, a substantial proportion of the existing literature has examined the effects of *C. sinensis* and *Daphne* species separately. In several studies, conclusions have relied mainly on wound size measurements or histological observations, while the relationships among microscopic repair features, lipid peroxidation status, antioxidant defense capacity, and tissue inflammatory intensity have received less attention. In particular, whether the combined topical application of hydroethanolic extracts of *C. sinensis* and *D. mucronata* can produce a stronger healing effect than either extract alone or silver sulfadiazine remains unresolved. This gap is particularly important in light of the possible complementarity of the two plants. Tea polyphenols may contribute mainly to oxidative stress control and inflammatory regulation, while bioactive metabolites of *D. mucronata* may further enhance therapeutic outcomes through their anti-inflammatory and cytoprotective properties and their potential to stimulate matrix regeneration. However, the possibility of a synergistic effect must be established through direct comparisons of the combined treatment with each single-extract treatment.

Accordingly, the main issue addressed in the present study is whether conventional topical treatments, despite their effectiveness in microbial control, adequately address the concurrent inflammatory, oxidative, and tissue-level disturbances within the wound microenvironment. Existing evidence regarding the healing effects of *C. sinensis* and *D. mucronata* remains fragmented and is based largely on separate assessments of these plants, while sufficient data on their combined effects and on the relationships between histopathological outcomes and biochemical markers remain limited. The present study therefore aims to determine whether combining these two extracts can improve tissue repair quality through the simultaneous modulation of inflammatory responses and oxidant-antioxidant balance, compared with each extract alone and with silver sulfadiazine.

The principal research question is whether the topical co-administration of hydroethanolic

[DOI: 10.18502/jabs.v16i4.22277]
Downloaded from jabs.fums.ac.ir at 7:16 +0330 on Sunday November 29th 2026

extracts of *Camellia sinensis* and *Daphne mucronata* in a rat cutaneous wound model can improve histopathological repair indices, reduce tissue TNF-α and MDA levels, and increase SOD activity more effectively than either extract administered alone or the reference treatment, silver sulfadiazine. The subsidiary questions address the extent to which each extract alone modulates inflammation, oxidative stress, and the microscopic structure of the repairing tissue; whether the combined treatment produces a stronger effect than either single-extract treatment; and whether improvements in biochemical indices are accompanied by reduced inflammatory cell infiltration, enhanced granulation tissue formation, greater re-epithelialization, and better collagen fiber organization.

The scientific value of this study lies in its integrated evaluation of three complementary levels of wound response: the inflammatory level, assessed through TNF-α measurement; the oxidative level, assessed through MDA and SOD measurements; and the structural level, evaluated through histopathological examination of wound tissue. Direct comparison of the single extracts, their combination, and silver sulfadiazine allows the effects of the individual treatments to be distinguished from potential additive or synergistic effects. This approach can clarify aspects of the biological mechanisms underlying the wound-healing effects of these plants and provide a preclinical foundation for developing multitarget, low-cost, plant-based topical formulations for human and veterinary medicine.

Therefore, the aim of this study was to compare the effects of hydroethanolic extracts of *C. sinensis* and *D. mucronata*, administered alone and in combination, with silver sulfadiazine on cutaneous wound healing in rats, with emphasis on histopathological changes and tissue levels of TNF-α and MDA, as well as SOD activity. The main hypothesis was that the combined application of these two extracts would improve the healing response through reductions in TNF-α levels and lipid peroxidation, enhancement of endogenous antioxidant defenses, and improved organization of the repairing tissue.

Materials and Methods

Plant collection and botanical authentication

Fresh leaves of *Camellia sinensis* (L.) Kuntze were collected in July 2024 from tea plantations in Lahijan, Gilan Province, northern Iran (37.1924° N, 50.0031° E). The aerial parts of *Daphne mucronata* Royle were collected in June 2024 from mountainous areas of the Zagros range in Kohgiluyeh and Boyer-Ahmad Province, southwestern Iran (30.6680° N, 51.5875° E). Both species were taxonomically identified by a senior plant taxonomist at the Herbarium of the Department of Biology, Shahid Chamran University of Ahvaz, Iran. Voucher specimens were deposited under accession numbers SCU-2024-CS for *C. sinensis* and SCU-2024-DM for *D. mucronata*.

Preparation and Phytochemical Standardization of Extracts

The collected plant materials were thoroughly washed with distilled water, shade-dried at room temperature (25 ± 2°C), and ground into a fine, uniform powder using an electric grinder.

Camellia sinensis Hydroethanolic Extract (CSHE)

One hundred grams of *C. sinensis* leaf powder was macerated in a 1:1 (v/v) mixture of absolute ethanol and distilled water. The mixture was continuously agitated on an orbital shaker (IKA, Staufen, Germany) for 48 h. The resulting mixture was filtered through Whatman No. 1 filter paper, and the solvent was removed under reduced pressure at 50°C. The concentrated extract was subsequently lyophilized to obtain a dry extract.

[DOI: 10.18502/jabs.v16i4.22277]
Downloaded from jabs.fums.ac.ir at 7:16 +0330 on Sunday November 29th 2026

Daphne mucronata Hydroethanolic Extract (DMHE)

The dried powder of *D. mucronata* was macerated in 80% (v/v) aqueous ethanol under continuous stirring for 72 h. The resulting suspension was filtered, and the filtrate was concentrated to dryness using a rotary evaporator (Heidolph Co., Schwabach, Germany) at 45°C. The extract was then dried further in an incubator to ensure complete removal of residual moisture.

Phytochemical Standardization

The phytochemical composition of the extracts was characterized and standardized by determining their total phenolic content (TPC) and total flavonoid content (TFC). TPC was determined using the Folin-Ciocalteu colorimetric assay. The results were calculated using a gallic acid calibration curve and expressed as milligrams of gallic acid equivalents per gram of dry extract (mg GAE/g dry extract). TFC was determined using the aluminum chloride colorimetric method and expressed as milligrams of quercetin equivalents per gram of dry extract (mg QE/g dry extract).

High-performance liquid chromatography coupled with ultraviolet detection (HPLC-UV) was used to investigate selected marker compounds. Epigallocatechin gallate (EGCG) was selected as the marker compound for *C. sinensis*, whereas daphnetin was selected as the marker compound for *D. mucronata*. The compounds were identified by comparing the retention times and chromatographic profiles of the samples with those of the corresponding reference standards.

Where quantitative determination was performed, EGCG and daphnetin concentrations were calculated using calibration curves prepared from the respective reference standards and expressed as milligrams per gram of dry extract (mg/g dry extract). The phytochemical characteristics of the extracts are summarized in Table 1.

Ointment preparation and dose selection

The dried extracts were incorporated into a hydrophilic ointment base consisting of Eucerin and Vaseline at a 1:1 ratio to prepare topical formulations with a final concentration of 5% (w/w).

The *C. sinensis* ointment was prepared by mixing 5 g of *C. sinensis* extract with 95 g of the ointment base. The *D. mucronata* ointment was prepared by mixing 5 g of *D. mucronata* extract with 95 g of the same base. The combined formulation was prepared by incorporating 2.5 g of *C. sinensis* extract and 2.5 g of *D. mucronata* extract into 95 g of the ointment base.

The selection of the 5% concentration was based on previous experimental evidence demonstrating favorable wound-healing activity of topical preparations containing *C. sinensis* and *D. mucronata* at this concentration, including accelerated re-epithelialization and acceptable dermal tolerability in rodents (15,20).

Animals and excisional wound model

Forty adult male Wistar rats, aged 8 to 12 weeks and weighing 175 to 190 g, were obtained from the breeding facility of Shahid Chamran University.

Table 1. Phytochemical Standardization of the Extracts.

Parameter	CSHE (Camellia sinensis)	DMHE (Daphne mucronata)
TPC (mg GAE/g dry extract)	245.20 ± 4.92	18.24 ± 1.35
TFC (mg QE/g dry extract)	68.40 ± 2.75	5.57 ± 0.42
EGCG (mg/g dry extract)	92.0 ± 2.0	ND
Daphnetin (mg/g dry extract)	ND	1.85 ± 0.14*

CSHE, Camellia sinensis hydroethanolic extract; DMHE, Daphne mucronata hydroethanolic extract; TPC, total phenolic content; TFC, total flavonoid content; EGCG, epigallocatechin gallate; GAE, gallic acid equivalents; QE, quercetin equivalents; ND, not detected.

[DOI: 10.18502/jabs.v16i4.22277]
Downloaded from jabs.fums.ac.ir at 7:16 +0330 on Sunday November 29th 2026

The animals were housed individually in polypropylene cages under controlled environmental conditions, with a temperature of 22 ± 2°C, relative humidity of 55 ± 5%, and a 12-h light/dark cycle. Standard rodent chow and filtered water were provided ad libitum. The animals were allowed to acclimatize for one week before the experimental procedures.

General anesthesia was induced by intraperitoneal administration of ketamine at 100 mg/kg and xylazine at 10 mg/kg. The dorsal thoracic region was shaved and disinfected with a 10% povidone-iodine solution. A circular, full-thickness excisional wound with an approximate area of 3 cm² was created in the mid-dorsal region, extending to the panniculus carnosus, using a sterile scalpel and surgical scissors (17).

Experimental design and treatment schedule

The animals were randomly assigned to five experimental groups, each containing eight rats:

1. Negative Control Group (NC): The animals received topical treatment once daily with the ointment vehicle alone, without any active ingredient.
2. Positive/Active Control Group (SSD): The animals received topical treatment once daily with 1% silver sulfadiazine (SSD) cream, which served as the clinical reference treatment for wound healing.
3. T1 Group (*Camellia sinensis*): The animals received topical treatment once daily with an ointment containing 5% (w/w) *C. sinensis* hydroethanolic extract (CSHE).
4. T2 Group (*Daphne mucronata*): The animals received topical treatment once daily with an ointment containing 5% (w/w) *D. mucronata* hydroethanolic extract (DMHE).
5. T3 Group (Combined Therapy): The animals received topical treatment once daily with an ointment containing a combination of CSHE and DMHE at a total concentration of 5% (w/w).

Topical treatment began on day 1 after wound induction and continued once daily throughout the study period. To evaluate the temporal progression of wound healing, the eight animals in each experimental group were divided into four time-point subgroups, with two rats assigned to each designated interval: days 3, 7, 14, and 21 post-wounding. At each predetermined time point, the designated animals, comprising two rats per experimental group, were euthanized by intraperitoneal administration of an overdose of sodium thiopental (150 mg/kg). Tissue samples were then collected for laboratory assessments.

Macroscopic wound assessment

Digital photographs of each wound were taken on days 0, 3, 7, 14, and 21 from a fixed distance under standardized conditions. Wound margins were traced, and wound areas were measured using digital calipers and image analysis software (Adobe Photoshop; Adobe Systems, San Jose, CA, USA). Wound contraction was expressed as a percentage of the initial wound area and calculated using the following equation:

$$\text{Wound contraction (\%)} = A0 - At \div A0 \times 100$$

where A0 represents the wound area on Day 0 and At represents the wound area on the corresponding post injury day.

Histopathological examination and morphometric analysis

Full-thickness skin specimens encompassing the wound bed and adjacent intact margins were collected on days 3, 7, 14, and 21. The tissues were fixed in 10% neutral buffered formalin, dehydrated through a graded ethanol series, cleared in xylene, and embedded in paraffin. Longitudinal sections with a thickness of 2 µm were prepared using a rotary microtome.

The sections were stained with hematoxylin and eosin to evaluate tissue architecture, inflammatory cell infiltration, and re-epithelialization. Masson's trichrome staining was performed to assess collagen

[DOI: 10.18502/jabs.v16i4.22277]
Downloaded from jabs.fums.ac.ir at 7:16 +0330 on Sunday November 29th 2026

deposition and fiber arrangement. Quantitative histomorphometric assessment included fibroblast counts, macrophage infiltration, microvessel density as an index of angiogenesis, and collagen fiber volume fraction. Measurements were obtained from five randomly selected high-power fields at 400× magnification using ImageJ software, version 1.53 (National Institutes of Health, Bethesda, MD, USA). Histological assessments were performed by a pathologist who was blinded to treatment allocation (20).

Biochemical Analyses

Immediately after collection, wound-bed samples intended for biochemical analysis were snap-frozen in liquid nitrogen and stored at −80°C. The tissues were homogenized in ice-cold phosphate-buffered saline (0.1 M, pH 7.4) using a SilentCrusher homogenizer (Heidolph Co., Germany) to prepare a 10% (w/v) homogenate. The homogenates were centrifuged at 10,000 × g for 15 min at 4°C, and the resulting supernatants were collected for biochemical analyses. Protein concentrations in the samples were determined using the Bradford assay to normalize tissue biomarker levels.

Inflammatory biomarker assay

Tissue TNF-α concentrations were measured using a rat-specific enzyme-linked immunosorbent assay (ELISA) kit (BioLegend Inc., San Diego, CA, USA), following the manufacturer's protocol. Optical density was measured at 450 nm using an ELx800 microplate reader (BioTek Instruments, Winooski, VT, USA). The results were expressed as picograms per milligram of protein (pg/mg protein).

Lipid peroxidation assay

Lipid peroxidation in wound tissue was evaluated by measuring malondialdehyde (MDA) concentrations using the thiobarbituric acid-reactive substances assay described by Ohkawa et al. (1979). Under acidic conditions and at an elevated temperature of 95°C, the tissue supernatants were reacted with thiobarbituric acid to produce a pink chromogen. Absorbance was then measured at 532 nm. The results were expressed as nanomoles per milligram of protein (nmol/mg protein).

Antioxidant enzyme assay

Superoxide dismutase (SOD) activity was measured using a colorimetric diagnostic kit (Pars Azmoon Co., Tehran, Iran) adapted for spectrophotometric analysis. The assay was based on the inhibition of nitroblue tetrazolium reduction by superoxide radicals. Enzyme activity was expressed as units per milligram of protein (U/mg protein).

Statistical Analysis

Quantitative data were expressed as the mean ± standard deviation (SD). Because the study variables were assessed at multiple time points, a repeated-measures two-way analysis of variance (ANOVA) was performed to evaluate the effects of group, time, and the group × time interaction. Partial eta squared ((\eta_p^2)) was calculated and reported as a measure of effect size.

When statistically significant differences were detected, pairwise comparisons between groups were performed using Tukey's post hoc test, as appropriate. Statistical analyses were conducted using SPSS version 21.0 (IBM Corp., Armonk, NY, USA). Figures were prepared using Microsoft Excel and OriginPro. Statistical significance was set at $P < 0.05$.

Results

Body Weight Dynamics and Growth Indices

Statistical analysis of body weight data revealed no significant differences among the experimental groups at baseline ($P = 0.271$), indicating that the groups were comparable before the intervention. However, by the end of the study (day 21), body weight differed significantly among the treatment groups ($P = 0.003$). According to Tukey's post hoc analysis, the T2 group, which received *Daphne mucronata*, exhibited a significantly lower body weight than the control, SSD, and T1 groups.

[DOI: 10.18502/jabs.v16i4.22277]
Downloaded from jabs.fums.ac.ir at 7:16 +0330 on Sunday November 29th 2026

Table 2. Comparison of Initial and Final Body Weights Across Experimental Groups.

Variables	Negative Control Group (NC)	Positive/Active Control Group (SSD)	Camellia (T1)	Daphne (T2)	Combined (T3)	P-value
Initial Weight (g)	179.82±0.49	177.11±2.37	178.83±4.30	184.89±2.93	185.08±3.60	0.271
Final Weight (g)	222.87±1.49[b]	221.79±5.33[e]	219.00±4.04[j]	201.62±4.15	209.10±4.61	0.003

In contrast, the remaining experimental groups maintained a pattern consistent with normal physiological growth (Table 2).

Data are expressed as mean ± standard error of the mean (SEM). Different superscript letters within each row indicate statistically significant differences ($P < 0.05$): b indicates a significant difference from T2; e indicates a significant difference between SSD and T2; and j indicates a significant difference between T1 and T2.

Histomorphometric Analysis of the Wound Healing Process

Microscopic findings, summarized in Table 2, demonstrated that all assessed wound-healing parameters in the treatment groups were significantly improved compared with those in the negative control group ($P < 0.001$).

- Re-epithelialization: The T1 (*Camellia sinensis*) group exhibited the highest percentage of epithelial regeneration (85.9 ± 0.70%), which was significantly higher than the corresponding values in the SSD, T2, and T3 groups.
- Granulation Tissue and Collagen Deposition: Fibroblast density and collagen maturation were markedly greater in the T1 and T3 groups than in the active control group (SSD).
- Angiogenesis: The T1 group achieved the highest scores for neovascularization and hair follicle formation (90 ± 1.38), highlighting the potential of *C. sinensis* extract to promote vascular development during wound repair.
- Inflammatory Response: The lowest inflammatory cell count was observed in the T3 group, which received the combined treatment (60 ± 0.96). This finding is consistent with a potential complementary effect of the two extracts in modulating the inflammatory response and promoting its resolution, although formal statistical testing is required to establish synergy.

Values are presented as mean ± standard deviation (SD) (n = 6 per group). Fibroblast density and collagen deposition were assessed using hematoxylin and eosin (H&E) and Masson's trichrome staining, respectively. Statistical significance was determined using one-way analysis of variance (ANOVA), followed by Tukey's post hoc test.

$P < 0.05$ compared with the negative control (NC); †$P < 0.05$ compared with the positive/active control (SSD). Letters (a-k) indicate statistically significant differences between specific groups ($P < 0.05$).

Macroscopic Analysis and Wound Contraction Rate

Wound Area

Wound area measurements for the experimental groups are presented in Table 3. At baseline, the mean wound areas were 1.41 ± 0.19 in the control group, 1.58 ± 0.23 in the silver sulfadiazine group, 0.83 ± 0.05 in T2, 1.77 ± 0.22 in T3, and 1.51 ± 0.17 in T1. On day 7, the corresponding values were 0.94 ± 0.14, 0.82 ± 0.07, 0.36 ± 0.03, 0.76 ± 0.20, and 0.76 ± 0.10, respectively. On day 14, the respective values were 0.21 ± 0.04, 0.21 ± 0.02, 0.07 ± 0.006, 0.16 ± 0.04, and 0.19 ± 0.01. By day 21, the wound areas had decreased to 0.14 ± 0.02 in the control group, 0.08 ± 0.008 in the silver sulfadiazine

[DOI: 10.18502/jabs.v16i4.22277]
Downloaded from jabs.fums.ac.ir at 7:16 +0330 on Sunday November 29th 2026

Table 3. Summary of Histopathological Indices and Wound Repair Progress on Day 21.

Healing Parameter	Negative Control Group (NC)	Positive/Active Control Group (SSD)	Camellia (T1)	Daphne (T2)	Combined (T3)	P-value
Epithelialization	70.0±0.59	80.0±0.8[a]	85.9±0.70[d,g,j,k]	80.0±1.03[b]	80.3±0.67[c]	<0.001
Fibroblasts	40±0.80	55±0.71[a]	75±0.46[d,g,j,k]	55±0.92[b]	70±0.89[c,f,h]	<0.001
Collagen Deposition	38±0.72	56±0.64[a]	78±0.52[dgjk]	52±0.85[b]	73±0.90[cfh]	<0.001
Angiogenesis	20±0.46	50±1.16[a]	90±1.38[d,g,j,k]	50±0.92[b]	75±1.43 [c,f,h]	<0.001
Inflammatory Cells	80±0.96[a,b,c,d]	70±1.16[f]	70±1.16[k]	70±0.96[h]	60±0.96	<0.001

group, 0.03 ± 0.005 in T2, 0.06 ± 0.009 in T3, and 0.03 ± 0.005 in T1.

Repeated-measures two-way analysis of variance revealed a significant main effect of treatment group on wound area ($P < 0.001$, partial $\eta^2 = 0.54$). A significant main effect of time was also observed ($P = 0.004$, partial $\eta^2 = 0.91$), indicating progressive wound contraction throughout the study period. The time-by-group interaction was statistically significant ($P < 0.001$, partial $\eta^2 = 0.94$), demonstrating that wound-area reduction followed different temporal patterns across the experimental groups.

Baseline comparisons revealed no statistically significant differences among the groups ($P > 0.05$). On day 7, the control group had a significantly larger wound area than T2, with a mean difference of 0.58 and a 95% confidence interval (CI) of 0.07 to 1.09. On day 14, both the control and silver sulfadiazine groups had larger wound areas than T2, with a reported mean difference of 0.13 and a 95% CI of 0.01 to 0.26. On day 21, the control group had a significantly larger wound area than the silver sulfadiazine, T2, T3, and T1 groups. The corresponding mean differences were 0.06, 0.11, 0.07, and 0.10, with 95% CIs of 0.01 to 0.11, 0.05 to 0.15, 0.02 to 0.12, and 0.05 to 0.15, respectively.

Figure 1 illustrates the progressive reduction in wound area across the experimental groups. T2 exhibited the steepest decline during the early and intermediate stages of wound repair, with the wound area decreasing to 0.07 ± 0.006 on day 14 and 0.03 ± 0.005 on day 21. By day 21, T1 had reached the same mean wound area as T2. The silver sulfadiazine group also exhibited a smaller wound area than the control group at the final assessment. Although T3 demonstrated a substantial reduction in wound area throughout the study, its residual wound area on day 21 remained greater than those in T1 and T2.

Percentage of Wound Healing

The percentages of wound healing in the experimental groups on days 7, 14, and 21 are presented in Table 4. On day 7, the mean healing percentages were 33.01 ± 1.45 in the control group, 45.04 ± 4.67 in the silver sulfadiazine group, 56.67 ± 1.35 in T2, 61.74 ± 5.79 in T3, and 50.23 ± 3.10 in T1. On day 14, the corresponding values were 85.84 ± 1.10, 86.07 ± 1.22, 90.81 ± 0.38, 92.08 ± 1.60, and 86.65 ± 0.92, respectively. By day 21, the wound-healing percentages had reached 89.90 ± 0.62 in the control group, 94.85 ± 0.55 in the silver sulfadiazine group, 96.10 ± 0.39 in T2, 96.16 ± 0.24 in T3, and 97.50 ± 0.11 in T1. Detailed comparisons of wound-healing percentages are presented in Table 5.

Repeated-measures two-way analysis of variance revealed statistically significant effects of treatment group, time, and the time-by-group interaction on the percentage of wound healing. The main effect of group was significant ($P < 0.001$, partial $\eta^2 = 0.54$), as was the main effect of time ($P = 0.004$, partial $\eta^2 = 0.91$).

[DOI: 10.18502/jabs.v16i4.22277]
Downloaded from jabs.fums.ac.ir at 7:16 +0330 on Sunday November 29th 2026

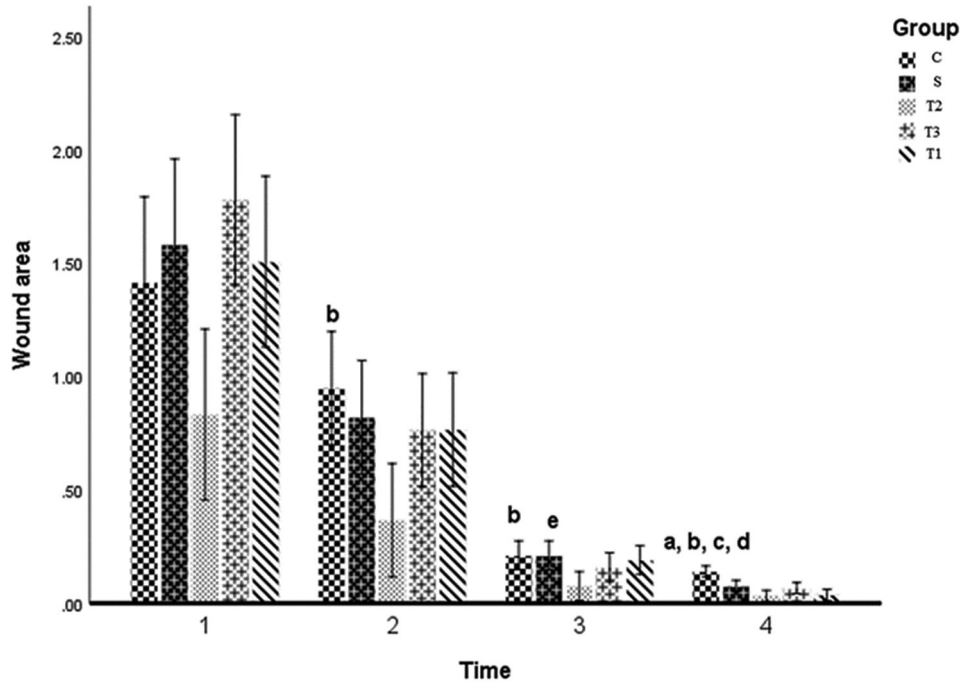

Figure 1. Mean wound area in the experimental groups.

Table 4. Comparison of wound area across the study groups.

Variable	Group	Day 0	Day 7	Day 14	Day 21	Main effect of time	Main effect of group	Time × group interaction
Wound area	Negative Control Group (NC)	1.41 ± 0.19	0.94 ± 0.14[b]	0.21 ± 0.04[b]	0.14 ± 0.02[abcd]	$p = 0.004$; partial $\eta^2 = 0.91$	$p < 0.001$; partial $\eta^2 = 0.54$	$p < 0.001$; partial $\eta^2 = 0.94$
	Positive/Active Control Group (SSD)	1.58 ± 0.23	0.82 ± 0.07	0.21 ± 0.02[e]	0.08 ± 0.008	—	—	—
	T2	0.83 ± 0.05	0.36 ± 0.03	0.07 ± 0.006	0.03 ± 0.005	—	—	—
	T3	1.77 ± 0.22	0.76 ± 0.20	0.16 ± 0.04	0.06 ± 0.009	—	—	—
	T1	1.51 ± 0.17	0.76 ± 0.10	0.19 ± 0.01	0.03 ± 0.005	—	—	—

Values are presented as mean ± standard deviation.
[a] Significant difference between the Negative Control Group and silver sulfadiazine groups.
[b] Significant difference between the Negative Control Group and T2 groups.
[c] Significant difference between the Negative Control Group and T3 groups.
[d] Significant difference between the Negative Control Group and T1 groups.
[e] Significant difference between the silver sulfadiazine and T2 groups.

The time-by-group interaction was also significant ($P < 0.001$, partial $\eta^2 = 0.94$). These findings indicate that the rate and extent of wound closure differed among the treatment groups over time.

On day 7, T2 exhibited a significantly higher wound-healing percentage than the control group, with a mean difference of 23.66 and a 95% CI of 8.55 to 38.77. T3 also demonstrated a significantly higher healing percentage than the control group, with a mean difference of 28.73 and a 95% CI of 13.62 to 43.83. Similarly,

[DOI: 10.18502/jabs.v16i4.22277]
Downloaded from jabs.fums.ac.ir at 7:16 +0330 on Sunday November 29th 2026

Table 5. Comparison of percentage wound healing across the study groups.

Variable	Group	Day 7	Day 14	Day 21	Main effect of time	Main effect of group	Time × group interaction
Percentage of wound healing	Negative Control (NC)	33.01 ± 1.45	85.84 ± 1.10	89.90 ± 0.62	$p = 0.004$; partial $\eta^2 = 0.91$	$p < 0.001$; partial $\eta^2 = 0.54$	$p < 0.001$; partial $\eta^2 = 0.94$
	Positive/Active Control (SSD)	45.04 ± 4.67[a]	86.07 ± 1.22	94.85 ± 0.55[a]	—	—	—
	T2	56.67 ± 1.35[b]	90.81 ± 0.38[be]	96.10 ± 0.39[b]	—	—	—
	T3	61.74 ± 5.79[c]	92.08 ± 1.60[cfk]	96.16 ± 0.24[c]	—	—	—
	T1	50.23 ± 3.10[d]	86.65 ± 0.92	97.50 ± 0.11[dg]	—	—	—

Values are presented as mean ± standard deviation.
[a] Significant difference between the Negative Control Group and Positive/Active Control Group (SSD) groups.
[b] Significant difference between the Negative Control Group and T2 groups.
[c] Significant difference between the Negative Control Group and T3 groups.
[d] Significant difference between the control and T1 groups.
[e] Significant difference between the Positive/Active Control Group (SSD) and T2 groups.
[f] Significant difference between Positive/Active Control Group (SSD) and T3 groups.
[g] Significant difference between the Positive/Active Control Group (SSD)and T1 groups.
[k] Significant difference between T3 and T1.

T1 exhibited a higher healing percentage than the control group, with a mean difference of 17.21 and a 95% CI of 2.11 to 32.32.

On day 14, T2 exhibited a significantly higher wound-healing percentage than the control group, with a mean difference of 4.97 and a 95% CI of 0.44 to 9.51. T2 also outperformed the silver sulfadiazine group, with a mean difference of 4.74 and a 95% CI of 0.20 to 9.27. T3 demonstrated a higher wound-healing percentage than the control, silver sulfadiazine, and T1 groups. The corresponding mean differences were 6.24, 6.01, and 5.43, with 95% CIs of 1.71 to 10.78, 1.47 to 10.54, and 0.89 to 9.96, respectively.

On day 21, the silver sulfadiazine, T2, T3, and T1 groups all exhibited significantly higher wound-healing percentages than the control group. The corresponding mean differences were 4.95, 6.20, 6.26, and 7.60, with 95% CIs of 3.19 to 6.71, 4.44 to 7.95, 4.50 to 8.02, and 5.84 to 9.35, respectively. In addition, T1 exhibited a significantly higher wound-healing percentage than the silver sulfadiazine group, with a mean difference of 2.65 and a 95% CI of 0.89 to 4.40.

Figure 2 illustrates the progressive increase in wound-healing percentages throughout the study period. The highest healing percentage on day 21 was observed in T1 (97.50 ± 0.11%), followed by T3 (96.16 ± 0.24%) and T2 (96.10 ± 0.39%). The silver sulfadiazine group achieved a healing percentage of 94.85 ± 0.55%, whereas the control group reached 89.90 ± 0.62%. The reported wound-healing percentages from baseline to day 21 were approximately 90.0% in the control group, 95.1% in the silver sulfadiazine group, 96.0% in T2, 96.2% in T3, and 97.5% in T1.

Figure 3 depicts the macroscopic progression of wound healing across the experimental groups on days 3, 7, 14, and 21. During the initial postoperative period, scab formation was observed in the wound beds of all groups. As healing progressed, wound areas decreased and epithelialization improved in the treated groups. By day 21, the groups receiving herbal extracts, particularly T1 and T3, exhibited advanced wound closure (Figure 3).

Journal of Advanced Biomedical Sciences
Fasa University of Medical Sciences

[DOI: 10.18502/jabs.v16i4.22277]
Downloaded from jabs.fums.ac.ir at 7:16 +0330 on Sunday November 29th 2026

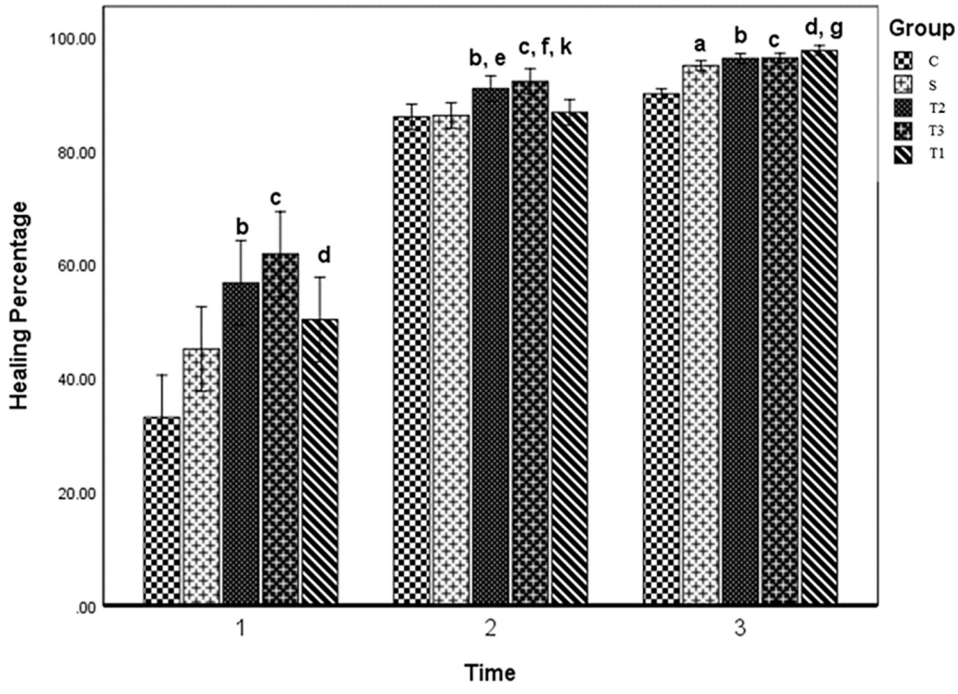

Figure 2. Mean percentage of wound healing in the experimental groups.

Descriptive Analysis of Histopathology

Figures 4 and 5 illustrate the microscopic progression of wound healing across the experimental groups, as assessed using hematoxylin and eosin (H&E) staining.

- T1 Group (*Camellia sinensis*): Microscopic examination revealed complete re-epithelialization and a well-defined stratum corneum. The granulation tissue contained developing vascular profiles, indicating active angiogenesis. However, the collagen fibers remained immature, and hair follicles were not yet evident.
- T2 Group (*Daphne mucronata*): Collagen bundle formation was evident. Both the epithelial layer and the stratum corneum had progressed toward advanced stages of maturation and were approaching completion.
- T3 Group (Combined Extract): The combined treatment was associated with well-organized, mature collagen fibers and bundles, together with well-developed vascular structures indicative of advanced angiogenesis. These findings suggest a potentially beneficial combined effect of the *Camellia* and *Daphne* extracts; however, formal statistical testing is necessary to determine whether this effect is synergistic.
- Negative Control Group: The negative control group exhibited the least evidence of healing progression. Angiogenesis was limited, and collagen maturation was less advanced than in the other experimental groups.
- Positive/Active Control Group (SSD): The silver sulfadiazine group exhibited evidence of successful tissue repair, characterized by mature collagen bundles and well-developed vascular structures, consistent with an active regenerative response.

Biochemical Assessment and Oxidative Stress Status

Tissue biochemical indices measured on day 21 are presented in Table 6. Significant differences among the experimental groups were observed in malondialdehyde (MDA)

[DOI: 10.18502/jabs.v16i4.22277]
Downloaded from jabs.fums.ac.ir at 7:16 +0330 on Sunday November 29th 2026

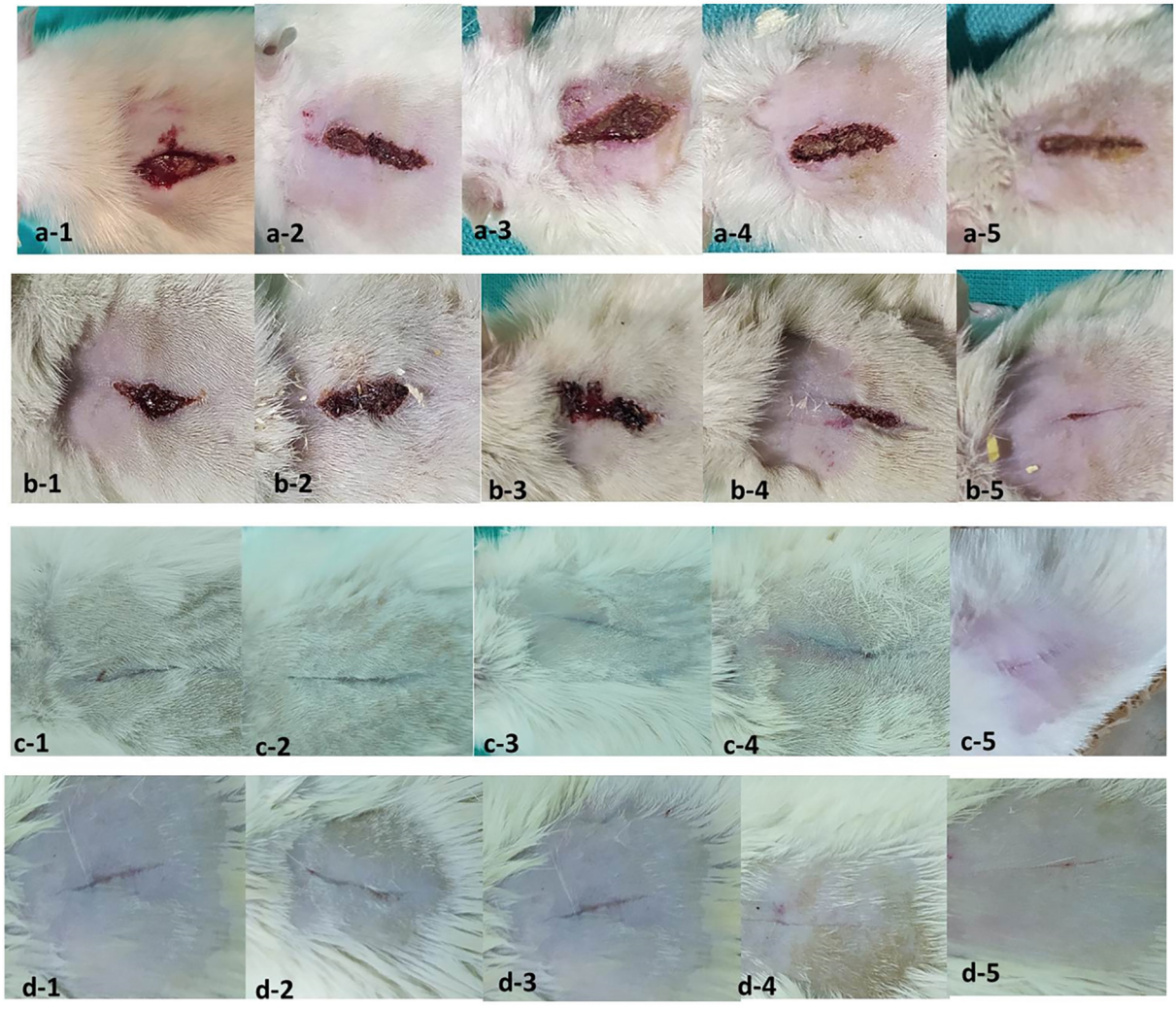

Figure 3. Macroscopic images of cutaneous wounds in experimental groups on days 3, 7, 14, and 21 post-injury. (a) Day 3: (a1) Negative Control Group, (a2) Positive/Active Control Group (SSD), (a3) Daphne mucronata-treated group, (a4) Camellia sinensis and Daphne mucronata combination group, (a5) Camellia sinensis-treated group. (b) Day 7: (b1) Negative Control Group, (b2) Positive/Active Control Group (SSD), (b3) D. mucronata-treated group, (b4) C. sinensis and D. mucronata combination group, (b5) C. sinensis-treated group. © Day 14: (c1) Negative Control Group, (c2) Positive/Active Control Group (SSD), (c3) D. mucronata-treated group, (c4) C. sinensis and D. mucronata combination group, (c5) C. sinensis-treated group. (d) Day 21: (d1) Control group, (d2) Positive/Active Control Group (SSD), (d3) D. mucronata-treated group, (d4) C. sinensis and D. mucronata combination group, (d5) C. sinensis-treated group.

concentrations, superoxide dismutase (SOD) activity, and tumor necrosis factor-alpha (TNF-α) concentrations. Overall, the biochemical profiles of the extract-treated groups indicated lower levels of oxidative stress and inflammation, accompanied by increased antioxidant enzyme activity.

MDA concentrations differed significantly among the groups on day 21 ($P < 0.05$). The control group exhibited the highest MDA concentration, at 8.1 ± 0.4 nmol/mg protein. The lowest concentration was observed in T1, at 3.2 ± 0.2 nmol/mg protein, followed by T3, at 3.9 ± 0.3 nmol/mg protein. Both T1 and T3 differed significantly from the control and silver sulfadiazine groups. T2 exhibited an intermediate MDA concentration of 4.8 ± 0.4 nmol/mg protein.

Journal of Advanced Biomedical Sciences
Fasa University of Medical Sciences

[DOI: 10.18502/jabs.v16i4.22277]
Downloaded from jabs.fums.ac.ir at 7:16 +0330 on Sunday November 29th 2026

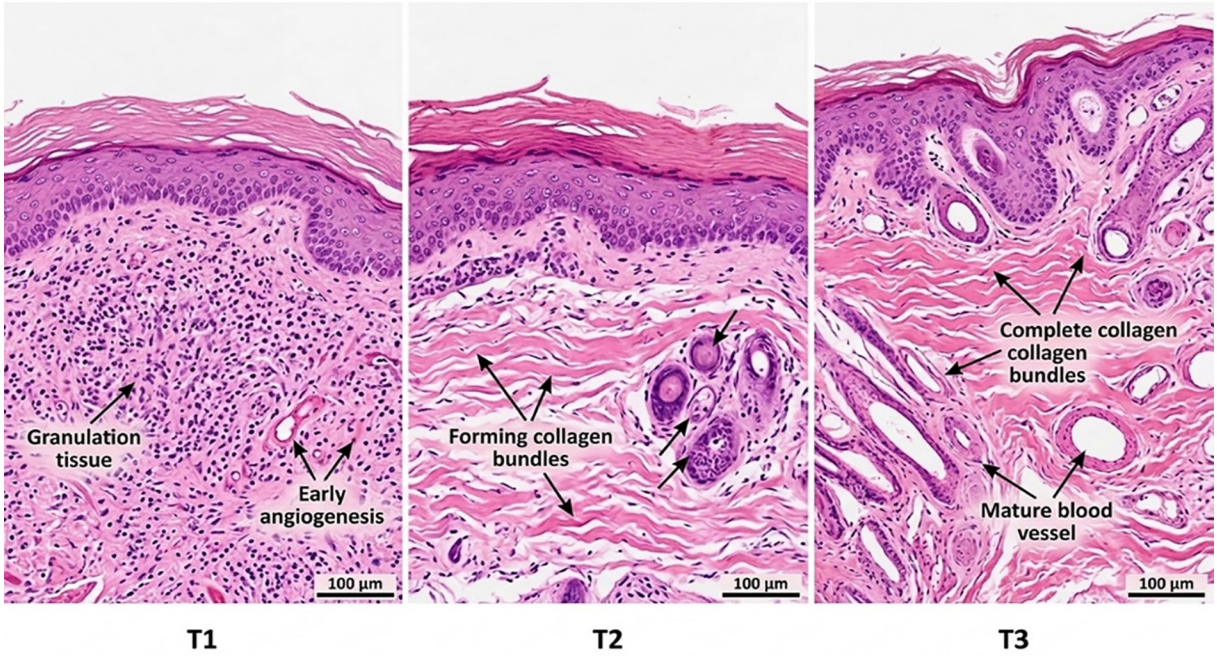

Figure 4. Histopathological evaluation of wound repair in the skin tissue of treatment groups (T1, T2, and T3). (H&E staining, 40× magnification).

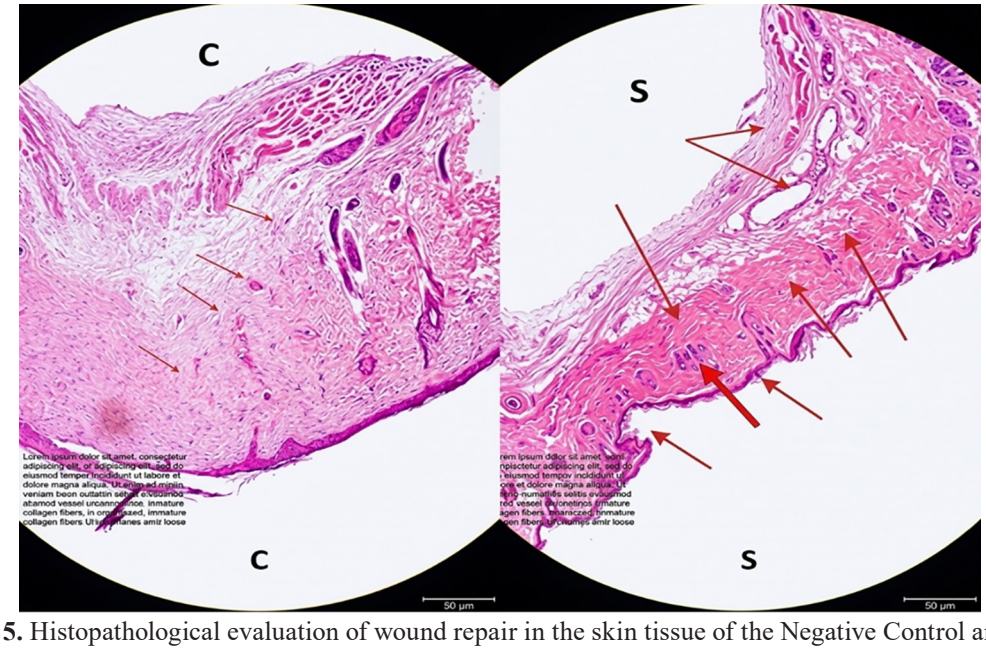

Figure 5. Histopathological evaluation of wound repair in the skin tissue of the Negative Control and Silver Sulfadiazine (SSD) groups. (H&E staining, 40× magnification).

SOD activity also differed significantly among the groups ($P < 0.05$). T1 exhibited the highest enzyme activity, with a mean value of 29.4 ± 2.2 U/mg protein. T3 showed the second-highest activity, at 24.8 ± 1.8 U/mg protein, followed by T2, at 20.1 ± 1.5 U/mg protein, and the silver sulfadiazine group, at 17.8 ± 1.6 U/mg protein. The control group exhibited the lowest activity, at 11.4 ± 1.2 U/mg protein. The significantly higher SOD activity in T1 than in the control and silver sulfadiazine groups indicated a pronounced antioxidant response.

[DOI: 10.18502/jabs.v16i4.22277]
Downloaded from jabs.fums.ac.ir at 7:16 +0330 on Sunday November 29th 2026

Table 6. Tissue biochemical profiles and oxidative stress markers on Day 21.

Biochemical marker	Negative Control Group (NC)	Positive/Active Control Group (SSD)	Camellia sinensis (T1)	Daphne mucronata (T2)	Combined treatment (T3)	P value
Malondialdehyde, nmol/mg protein	8.1 ± 0.4[a]	5.4 ± 0.35	3.2 ± 0.2*	4.8 ± 0.4	3.9 ± 0.3*	< 0.05
Superoxide dismutase, U/mg protein	11.4 ± 1.2	17.8 ± 1.6	29.4 ± 2.2*	20.1 ± 1.5	24.8 ± 1.8	< 0.05
Tumor necrosis factor alpha, pg/mg protein	162 ± 12[a]	105 ± 9.1	68 ± 6*	98 ± 8	74 ± 5*	< 0.01

Values are presented as mean ± standard deviation (SD); n = 6 per group.
* P < 0.05 vs. the negative control group (NC).
† P < 0.05 vs. the positive/active control group (SSD) (oneway ANOVA followed by Tukey's post hoc test).

TNF-α concentrations differed significantly among the experimental groups ($P < 0.01$). T1 exhibited the lowest TNF-α concentration (68 ± 6 pg/mg protein), followed by T3 (74 ± 5 pg/mg protein). Both values differed significantly from those of the control and silver sulfadiazine groups. The TNF-α concentration in T2 was 98 ± 8 pg/mg protein, whereas that in the silver sulfadiazine group was 105 ± 9.1 pg/mg protein, according to the re-evaluated raw data. The highest TNF-α concentration was observed in the control group, at 162 ± 12 pg/mg protein.

Figure 6 presents the biochemical and inflammatory profiles of wound tissue on day 21,

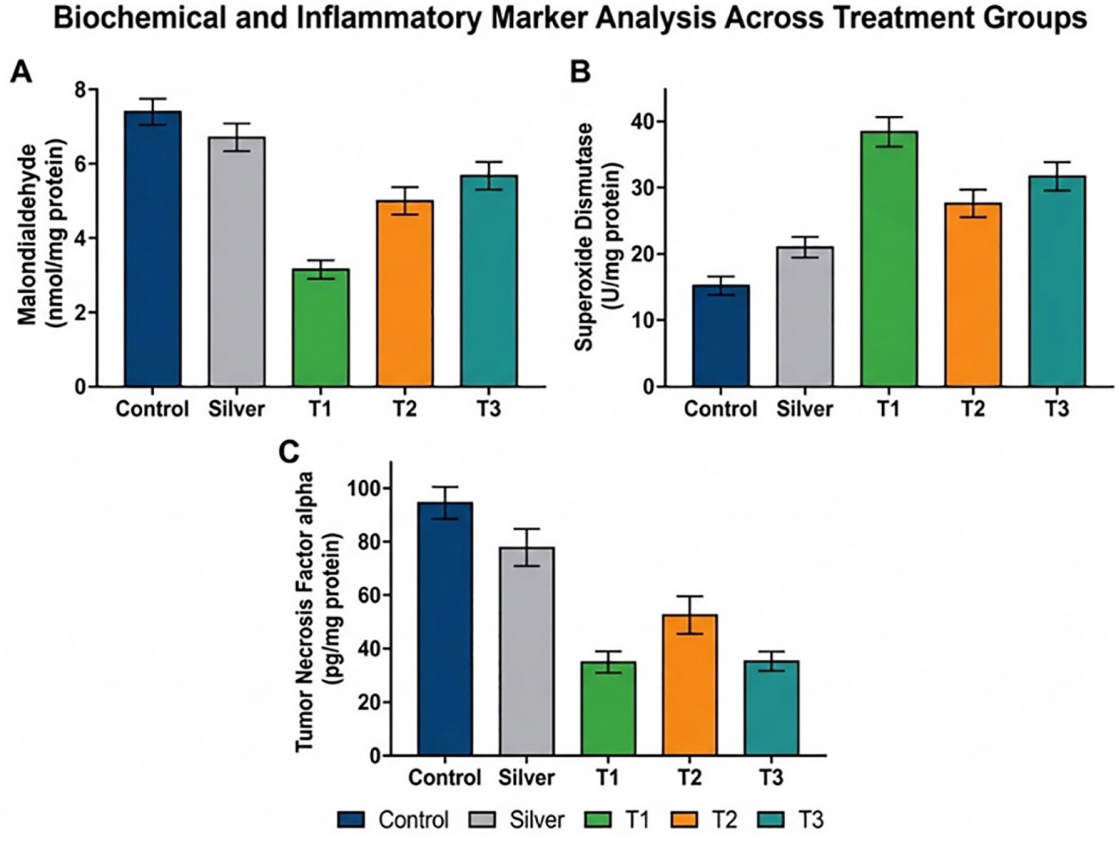

Figure 6. Comparison of biochemical and inflammatory markers in wound tissue across experimental groups on Day 21. A) Tissue malondialdehyde (MDA) concentration, (B) superoxide dismutase (SOD) activity, and © tissue tumor necrosis factor-alpha (TNF-α) concentration.

[DOI: 10.18502/jabs.v16i4.22277]
Downloaded from jabs.fums.ac.ir at 7:16 +0330 on Sunday November 29th 2026

as assessed by MDA concentrations, SOD activity, and TNF-α concentrations across all experimental groups.

The control group exhibited the highest MDA and TNF-α levels, whereas T1 showed the lowest MDA concentration and one of the lowest TNF-α concentrations. SOD activity was highest in T1 and lowest in the control group. T3 also demonstrated substantial improvements relative to the control and silver sulfadiazine groups, as reflected by lower MDA and TNF-α levels and higher SOD activity. Data are presented as mean ± SD.

Discussion

Cutaneous wound healing is a multistage process involving hemostasis, inflammation, cellular proliferation, granulation tissue formation, angiogenesis, re-epithelialization, and extracellular matrix remodeling. The temporal coordination of these processes determines the quality of wound closure and the structural characteristics of the repaired tissue (1,3,21). In the present study, the topical application of *Camellia sinensis* and *Daphne mucronata* extracts was associated with improvements in macroscopic, histomorphometric, and biochemical indices of wound repair. However, the response patterns varied among the treatment groups, with each intervention exerting more pronounced effects on specific aspects of the healing process.

Body Weight Changes and Safety Considerations

The absence of significant differences in baseline body weight among the experimental groups (P = 0.27) indicated adequate comparability before treatment. By day 21, however, body weight differed significantly among the groups (P = 0.003), with the *D. mucronata* group exhibiting the lowest body weight (201.62 ± 4.15 g) compared with the control, positive control, and *C. sinensis* groups. Although this change coincided with accelerated wound repair in T2, the observed reduction in body weight warrants careful interpretation in terms of both therapeutic efficacy and systemic safety.

Studies investigating the genus *Daphne* have identified bioactive constituents with diverse pharmacological properties. Given the variation in chemical composition, concentration, extraction procedures, and routes of administration, the safety of each preparation must be evaluated individually (19,22). Accordingly, the lower body weight observed in T2 represents an important finding that warrants further investigation. Future studies should assess food and water intake, behavioral changes, hepatic and renal function, hematological parameters, and histopathological alterations in the liver, kidneys, and gastrointestinal tract. Such assessments would help distinguish the local therapeutic effects of the formulation from potential systemic adverse effects.

Effects of Treatments on Wound Area Reduction and Healing Percentage

Repeated-measures analysis of variance revealed significant effects of time, treatment group, and the time-by-group interaction on both wound area and wound-healing percentage. The large effect sizes reported for time (partial η^2 = 0.91) and the time-by-group interaction (partial η^2 = 0.94) indicate distinct healing trajectories across the experimental groups. These findings suggest that wound area reduction was influenced by both the duration of the healing process and the type of treatment, with treatment-related differences emerging in the temporal progression of tissue repair.

On day 7, T3 exhibited the highest wound-healing percentage (61.74 ± 5.79%), while T2 also demonstrated substantial improvement (56.67 ± 1.35%) relative to the control group. By day 14, T3 had achieved the highest healing percentage (92.08 ± 1.60%), with significant differences compared with the control, silver

[DOI: 10.18502/jabs.v16i4.22277]
Downloaded from jabs.fums.ac.ir at 7:16 +0330 on Sunday November 29th 2026

sulfadiazine, and T1 groups. This finding suggests that the combined treatment may be particularly beneficial during the intermediate phase of wound repair, when fibroblast proliferation, granulation tissue formation, extracellular matrix synthesis, and angiogenesis play important roles in tissue regeneration (13,24).

By day 21, T1 exhibited the highest wound-healing percentage (97.50 ± 0.11%), which was significantly greater than that of the silver sulfadiazine group. The wound areas in T1 and T2 both reached 0.03 ± 0.0050, representing the lowest values among the experimental groups. These findings suggest that *C. sinensis* had a more pronounced effect on late-stage macroscopic wound closure, whereas *D. mucronata* was associated with more rapid wound area reduction during the early and intermediate stages. Such temporal differences may reflect variations in the active constituents of the extracts and their potential effects on inflammatory regulation, oxidative status, keratinocyte migration, and fibroblast activity.

The present findings are consistent with previous animal studies investigating the wound-healing potential of *C. sinensis*. Asadi Seyedyazdan et al. (18) investigated the effects of green tea extract on surgical and burn wound healing in rats. Karimi et al. (16), Fatemi et al. (25), Hajiaghaalipour et al. (15), and Kouhihabibidehkordi et al. (17) also reported improved wound repair following the administration of tea-derived preparations in animal models. Polyphenols and catechins, particularly epigallocatechin gallate (EGCG), are major bioactive constituents of green tea and may contribute to the regulation of oxidative status, inflammatory responses, and cellular activity during tissue repair (14,26,27).

Histological and Histomorphometric Evidence

Histomorphometric findings on day 21 indicated that all treatment groups exhibited more favorable outcomes than the control group in terms of re-epithelialization, fibroblast count, collagen deposition, angiogenesis, and inflammatory cell infiltration ($P < 0.001$). In T1, re-epithelialization reached 85.9 ± 0.70%, the reported fibroblast count and collagen deposition value was 75 ± 0.46, and the angiogenesis score reached 90 ± 1.38. These were the highest reported values among the experimental groups. The findings were consistent with the histological observations of substantial epithelial reconstruction, a well-defined stratum corneum, and vascular profiles within the granulation tissue.

Re-epithelialization depends on keratinocyte migration and proliferation, as well as interactions between the regenerating epithelium and the extracellular matrix (21,28). The findings reported by Chan et al. (29) regarding the effects of EGCG on cellular migration and adhesion, together with those of Er and Dikmen (30) on the wound-healing potential of *C. sinensis* in a fibroblast model, provide a basis for interpreting the improved re-epithelialization and fibroblastic activity observed in T1. Nevertheless, the presence of immature collagen fibers and the absence of detectable hair follicles in T1 on day 21 indicate that surface closure and complete restoration of skin architecture are distinct biological outcomes. Collagen remodeling and the regeneration of skin appendages may require longer periods, highlighting the importance of extending follow-up beyond day 21 to assess these processes adequately (2,31).

In T2, the presence of formed collagen bundles and the advanced maturation of the epithelium and stratum corneum provided further evidence of tissue repair. Together with the reduction in wound area observed on days 7, 14, and 21, these findings support the potential role of *D. mucronata* in promoting wound healing. Previous studies have also reported wound-healing activity in other species of the genus *Daphne*. Süntar et al. (19) investigated

[DOI: 10.18502/jabs.v16i4.22277]
Downloaded from jabs.fums.ac.ir at 7:16 +0330 on Sunday November 29th 2026

the wound-healing effects of *Daphne oleoides* subsp. *kurdica* in an experimental wound model, whereas Karimi et al. (20) reported improved excisional wound healing using an alginate dermal scaffold loaded with a hydroalcoholic extract of *D. mucronata*. Nevertheless, findings from other *Daphne* species cannot be directly extrapolated to *D. mucronata*, because phytochemical composition and biological activity may vary according to species, plant organ, and extraction method (22).

Microscopic examination of T3 revealed more mature and better-organized collagen fibers, together with more developed vascular structures. This group also exhibited the lowest inflammatory cell count (60 ± 0.96). Collectively, these findings suggest that the combined treatment was associated with improved tissue remodeling and reduced inflammatory cell infiltration on day 21. However, establishing pharmacological synergy requires an experimental design and statistical approach specifically suited to evaluating interactions between the extracts. Although T3 showed advantages for selected outcomes, T1 exhibited the highest re-epithelialization and angiogenesis scores and the highest day-21 wound-healing percentage, while T1 and T2 had the smallest residual wound areas. Therefore, the findings suggest that the two extracts may have complementary effects on selected wound-healing indices, but they do not establish pharmacological synergy. Confirmation of such an effect would require dose-response studies, evaluation of different combination ratios, and quantitative drug-interaction analyses.

Oxidative Status and Inflammation in Wound Tissue

Increased reactive oxygen species production during the early stages of wound repair contributes to host defense and cellular signaling. However, persistent oxidative stress can promote lipid peroxidation, membrane damage, cellular dysfunction, and delayed tissue repair (3,5). In the present study, the MDA concentration in the control group was 8.1 ± 0.4 nmol/mg protein, whereas concentrations decreased to 3.2 ± 0.2 and 3.9 ± 0.3 nmol/mg protein in T1 and T3, respectively. These reductions indicate lower levels of lipid peroxidation in the wound tissue of the corresponding treatment groups.

SOD activity was highest in T1 (29.4 ± 2.2 U/mg protein), while T3 also exhibited higher activity than the control group (24.8 ± 1.8 U/mg protein). SOD is an important component of the endogenous antioxidant defense system that catalyzes the conversion of superoxide radicals into hydrogen peroxide. The increased activity of this enzyme, together with reduced MDA concentrations, supports the interpretation that the botanical extracts modulated oxidative status in the wound tissue. The antioxidant properties of tea phenolic compounds have been documented in several studies (6,13,32). Tajammal et al. (27) also discussed the potential role of green tea polyphenols in modulating wound inflammation and oxidative stress.

The TNF-α concentration was 162 ± 12 pg/mg protein in the control group, compared with 68 ± 6 and 74 ± 5 pg/mg protein in T1 and T3, respectively. These lower concentrations, together with the reduced inflammatory cell count observed in T3, are consistent with attenuation of persistent inflammation in the wound tissue. Appropriate regulation of macrophage activity and inflammatory mediator signaling is necessary for the initiation and progression of tissue repair, whereas prolonged inflammation can impair granulation tissue formation and extracellular matrix remodeling (4,33). Accordingly, the biochemical profiles of T1 and T3 were consistent with the macroscopic and histological findings observed in these groups.

Comparison with Silver Sulfadiazine

Silver sulfadiazine, which served as the

[DOI: 10.18502/jabs.v16i4.22277]
Downloaded from jabs.fums.ac.ir at 7:16 +0330 on Sunday November 29th 2026

active control, reduced wound area and increased the wound-healing percentage compared with the negative control. On day 21, the healing percentage in the silver sulfadiazine group was 94.85 ± 0.55%, exceeding that of the control group but remaining below that of T1. Histological examination also revealed mature collagen bundles and well-developed vascular structures in the silver sulfadiazine group. These findings are consistent with the established use of silver sulfadiazine in burn-wound management, although its effects may vary according to wound type, treatment duration, and formulation (8,34,35).

The higher day-21 healing percentage observed in T1 relative to silver sulfadiazine, together with the greater reductions in MDA and TNF-α concentrations and the higher SOD activity, highlights the potential of *C. sinensis* extract in this animal model. However, these results should not be interpreted as definitive evidence of therapeutic superiority in human wounds. Acute cutaneous wounds in healthy animals differ biologically from chronic, diabetic, ischemic, infected, or extensive burn wounds. Translation of these findings into clinical practice will require further evaluation of extract standardization, dermal safety, formulation stability, active-compound release, and efficacy in disease-specific wound models.

Significance and Novelty of the Study

The principal contribution of this study lies in its integrated evaluation of macroscopic wound indices, including wound area and healing percentage, histomorphometric variables, and biochemical markers of oxidative stress and inflammation. This comprehensive approach enables the relationships among reduced MDA and TNF-α concentrations, increased SOD activity, decreased inflammatory cell infiltration, fibroblast activity, collagen deposition, angiogenesis, and wound closure to be examined within a single experimental framework. Furthermore, the direct comparison of *C. sinensis*, *D. mucronata*, their combination, and silver sulfadiazine provides a basis for further investigation of plant-derived topical formulations.

The findings indicate that *C. sinensis* was particularly effective in terms of re-epithelialization, angiogenesis, SOD activity, and the day-21 wound-healing percentage. In contrast, the combined treatment was associated with the lowest inflammatory cell count, a reduced TNF-α concentration, and more mature collagen organization. The *D. mucronata* group also exhibited substantial wound area reduction during the early and intermediate stages of healing. These differences suggest that the selection of an individual extract or a combination may depend on the intended therapeutic outcome, stage of wound healing, safety profile, concentration, and formulation.

Limitations

Several limitations should be considered when interpreting these findings. First, the study was conducted using a rat cutaneous wound model; therefore, the results cannot be directly extrapolated to human clinical settings. Second, the 21-day follow-up period may have been insufficient to capture long-term collagen remodeling and the regeneration of skin appendages. Third, although the biochemical and histomorphometric findings provide evidence of changes in oxidative and inflammatory status, additional molecular analyses are needed to elucidate the underlying mechanisms. Finally, further dose-response and safety studies are warranted, particularly for *D. mucronata*, in view of the observed difference in body weight in T2. Future investigations should incorporate longer follow-up periods, comprehensive systemic safety assessments, phytochemical standardization, and evaluation in clinically relevant wound models.

Conclusion

Topical application of *Camellia sinensis*,

[DOI: 10.18502/jabs.v16i4.22277]
Downloaded from jabs.fums.ac.ir at 7:16 +0330 on Sunday November 29th 2026

Daphne mucronata, and their combination improved wound repair compared with the negative control in a rat cutaneous wound model. The *C. sinensis* group exhibited the highest day-21 wound-healing percentage, the greatest degree of re-epithelialization, the highest angiogenesis score, the highest SOD activity, and the lowest MDA concentration. The combined treatment group exhibited the lowest inflammatory cell count on day 21 and was associated with more mature collagen fibers and more developed vascular structures on histological examination. The *D. mucronata* group also showed substantial wound area reduction during the early and intermediate stages of healing, although the associated reduction in body weight underscores the need for further investigation of systemic safety.

Overall, these findings support the potential of the investigated botanical extracts as candidates for the further development of topical wound-healing formulations. Nevertheless, definitive conclusions regarding therapeutic superiority or pharmacological synergy should be reserved until additional dose-response, mechanistic, long-term safety, and clinically relevant wound-model studies have been conducted.

Acknowledgments

The authors thank the Avin-Bonyan-Gene Research Center, affiliated with Shahid Chamran University of Ahvaz, for its technical support throughout the experimental procedures.

Conflict of Interest

The authors declare that they have no conflict of interest regarding the publication of this research.

Funding

This research received no specific grant from any funding agency in the public, commercial, or nonprofit sectors.

Ethical Considerations

This experimental study was conducted in accordance with the *Guide for the Care and Use of Laboratory Animals* (NIH Publication No. 85-23, revised 2011). Ethical approval was granted by the Bioethics Committee of Islamic Azad University, Ahvaz Branch, Ahvaz, Iran. Animal housing, surgical wound induction, daily monitoring, tissue sampling, and postoperative care were performed at the Laboratory Animal Breeding and Research Center of Shahid Chamran University of Ahvaz, Ahvaz, Iran.

Code of Ethics

The ethical approval code for this study is IR.IAU.AHVAZ.REC.1403.484, issued by the Bioethics Committee of Islamic Azad University, Ahvaz Branch, Ahvaz, Iran.

Authors' Contributions

All authors contributed equally to the study design, data collection, statistical analysis, and preparation of this manuscript. All authors have read and approved the final version of the article.

References

1 Gonzalez AC, Costa TF, Andrade ZA, Medrado AR. Wound healing: a literature review. A Bras Dermatol. 2016;91(5):614-20. doi:10.1590/abd1806-4841.20164741.
2 Martin P. Wound healing: aiming for perfect skin regeneration. Science. 1997;276(5309):75-81. doi:10.1126/science.276.5309.75.
3 Eming SA, Krieg T, Davidson JM. Inflammation in wound repair: molecular and cellular mechanisms. J Invest Dermatol. 2007;127(3):514-25. doi:10.1038/sj.jid.5700701.
4 Hassanshahi A, Moradzad M, Ghalamkari S, Fadaei M, Cowin AJ, Hassanshahi M. Macrophage-mediated inflammation in skin wound healing. Cells. 2022;11(19):2953. doi:10.3390/cells11192953.

[DOI: 10.18502/jabs.v16i4.22277]
Downloaded from jabs.fums.ac.ir at 7:16 +0330 on Sunday November 29th 2026

5 Chen J, Liu Y, Zhao Z, Qiu J. Oxidative stress in the skin: impact and related protection. Int J Cosmet Sci. 2021;43(5):495-509. doi:10.1111/ics.12728.
6 Działo M, Mierziak J, Korzun U, Preisner M, Szopa J, Kulma A. The potential of plant phenolics in prevention and therapy of skin disorders. Int J Mol Sci. 2016;17(2):160. doi:10.3390/ijms17020160.
7 Ohkawa H, Ohishi N, Yagi K. Assay for lipid peroxides in animal tissues by thiobarbituric acid reaction. Anal Biochem. 1979;95(2):351-8. doi:10.1016/0003-2697(79)90738-3.
8 Yaman I, Durmus AS, Ceribasi S, Yaman M. Effects of Nigella sativa and silver sulfadiazine on burn wound healing in rats. Vet Med (Praha). 2010;55(12):619-24. doi:10.17221/2967-VETMED.
9 Albahri G, Badran A, Hijazi A, Daou A, Baydoun E, Nasser M, et al. The therapeutic wound healing bioactivities of various medicinal plants. Life (Basel). 2023;13(2):317. doi:10.3390/life13020317.
10 Criollo-Mendoza MS, Contreras-Angulo LA, Leyva-López N, Gutiérrez-Grijalva EP, Jiménez-Ortega LA, Heredia JB. Wound healing properties of natural products: mechanisms of action. Molecules. 2023;28(2):598. doi:10.3390/molecules28020598.
11 Akhtari N, Ahmadi M, Kiani Doust Vaghe Y, Asadian E, Behzad S, Vatanpour H, et al. Natural agents as wound healing promoters. Inflammopharmacology. 2024;32(1):101-25.
12 Saikia K, Dutta PP, Aziz Barbhuiya SA. A comprehensive review on the role of medicinal plants in the management of diabetic wound: a mechanistic insight. Curr Drug Res Rev. 2025;17. doi:10.2174/0125899775395717250903190844.
13 Rietveld A, Wiseman S. Antioxidant effects of tea: evidence from human clinical trials. J Nutr. 2003;133(10):3285S-92S. doi:10.1093/jn/133.10.3285S.
14 Teixeira AM, Sousa C. A review on the biological activity of Camellia species. Molecules. 2021;26(8):2178. doi:10.3390/molecules26082178.
15 Hajiaghaalipour F, Kanthimathi MS, Abdulla MA, Sanusi J. The effect of Camellia sinensis on wound healing potential in an animal model. Evid Based Complement Alternat Med. 2013;2013:386734. doi:10.1155/2013/386734.
16 Karimi M, Parsaei P, Asadi SY, Ezzati S, Boroujeni RK, Zamiri A, et al. Effects of Camellia sinensis ethanolic extract on histometric and histopathological healing process of burn wound in rat. Middle East J Sci Res. 2013;13(1):14-9. doi:10.5829/idosi.mejsr.2013.13.1.66118.
17 Kouhihabibidehkordi G, Kheiri S, Karimi I, Taheri F, Bijad E, Bahadoram M, et al. Effect of white tea (Camellia sinensis) extract on skin wound healing process in rats. World J Plast Surg. 2021;10(1):85-95. doi:10.29252/wjps.10.1.85.
18 Asadi Seyedyazdan S, Zamiri A, Ezzati S, Parsaei P, Rafieeian M, Shirzad H. Effect of alcoholic green tea extract (Camellia sinensis) on the healing process of surgical and burn wounds in rats. J Birjand Univ Med Sci. 2011;18(1):1-9.
19 Süntar I, Küpeli Akkol E, Keleş H, Yeşilada E, Sarker SD, Arroo R, et al. Efficacy of Daphne oleoides subsp. kurdica used for wound healing: identification of active compounds through bioassay-guided isolation technique. J Ethnopharmacol. 2012;141(3):1058-70. doi:10.1016/j.jep.2012.04.001.
20 Karimi SA, Abdolmaleki A, Sadeghi A, Naseri S, Ayni M, Gholami MR. Drug delivery system through alginate dermal scaffold loaded with hydroalcoholic extract of Daphne mucronata improves dermal excisional wound healing: an experimental research. Regen Eng Transl Med. 2022;8(4):523-34. doi:10.1007/s40822-022-00213-3.
21 Shaw TJ, Martin P. Wound repair at a glance. J Cell Sci. 2009;122(18):3209-13.
22 Khouchlaa A, El Menyiy N, Guaouguaou FE, El Baaboua A, Charfi S, Lakhdar F, et al. Ethnomedicinal use, phytochemistry, pharmacology, and toxicology of Daphne gnidium: a review. J Ethnopharmacol. 2021;275:114124. doi:10.1016/j.jep.2021.114124.
23 Clark RAF. Biology of dermal wound repair. Dermatol Clin. 1993;11:647-66.
24 Potekaev NN, Borzykh OB, Medvedev GV, Pushkin DV, Petrova MM, Petrov AV, et al. The role of extracellular matrix in skin wound healing. J Clin Med. 2021;10(24):5947. doi:10.3390/jcm10245947.
25 Fatemi MJ, Nikoomaram B, Rahimi AAK, Talayi D, Taghavi S, Ghavami Y. Effect of green tea on the second degree burn wounds in rats. Indian J Plast Surg. 2014;47(3):370-4.
26 Koch W, Zagórska J, Marzec Z, Kukula-Koch W. Applications of tea (Camellia sinensis) and its active constituents in cosmetics. Molecules. 2019;24(23):4277. doi:10.3390/molecules24234277.
27 Tajammal SA, Coffey A, Tan SP. Green tea polyphenols in wound healing: therapeutic mechanisms, potential applications and challenges in commercial use for diabetic wound healing. Processes. 2025;13(3):653. doi:10.3390/pr13030653.
28 Li J, Chen J, Kirsner R. Pathophysiology of acute wound healing. Clin Dermatol. 2007;25:9-18.
29 Chan CM, Huang JH, Chiang HS, Wu WB, Lin HH, Hong JY, et al. Effects of epigallocatechin gallate on

[DOI: 10.18502/jabs.v16i4.22277]
Downloaded from jabs.fums.ac.ir at 7:16 +0330 on Sunday November 29th 2026

retinal pigment epithelial cell migration and adhesion. Mol Vis. 2010;16:586-95.
30 Er S, Dikmen M. Camellia sinensis increased apoptosis on U2OS osteosarcoma cells and wound healing potential on NIH3T3 fibroblast cells. Cytotechnology. 2017;69:901-14.
31 Midwood KS, Williams LV, Schwarzbauer JE. Tissue repair and the dynamics of the extracellular matrix. Int J Biochem Cell Biol. 2004;36:1031-7.
32 Zielinski AAF, Haminiuk CWI, Alberti A, Nogueira A, Demiate IM, Granato D. A comparative study of phenolic compounds and in vitro antioxidant activity of different Brazilian teas using multivariate statistical techniques. Food Res Int. 2014;60:246-54.
33 Rodero MP, Khosrotehrani K. Skin wound healing modulation by macrophages. Int J Clin Exp Pathol. 2010;3(7):643-53.
34 Azevedo EP, Saldanha TDP, Navarro MVM, Raffin FN. Mechanical properties and release studies of chitosan films impregnated with silver sulfadiazine. J Appl Polym Sci. 2006;102:3462-70.
35 Hosseinimehr SJ, Khorasani G, Azadbakht M, Zamani P, Ghasemi M, Ahmadi A. Effect of Aloe cream versus silver sulfadiazine for healing burn wounds in rats. Acta Dermatovenerol Croat. 2010;18(1):2-7.