



Original Article

## Protective Effects of Vitamin D on Testicular Tissue, Oxidative Stress and Apoptotic Genes Expression in Rats Treated with Simvastatin

Kiyarad Edris<sup>1</sup>, Najafi Tazekand GH<sup>2\*</sup>, Farrocki Farrah<sup>1</sup>

1. Department of Biology, Faculty of Science, Urmia University, Urmia, Iran

2. Department of Anatomy and Embryology, Faculty of Veterinary Medicine, Urmia University, Urmia, Iran

Received: 25 Jul 2021

Accepted: 16 Aug 2021

### Abstract

**Background & Objective:** Cardiovascular diseases (CVDs) are the deadliest disease globally, which in order to reduce this mortality rate statin has been used during last decades. In line, it has been revealed that statins negatively affect testicular tissue. Thus, in the current project, we aimed to investigate the vitamin D protective effects during simvastatin (SIM) administration.

**Materials & Methods:** In this project, 48 male mature Wistar rats were randomly divided into 6 control and experimental groups. The experimental groups were subdivided into Low and High dose SIM-received and Vitamin D co-treated SIM-received groups. After 45 days, the body weight of the animal groups was measured and then they were euthanized and testicles were removed. The right testicular tissue was fixed in fixative solution, while the left testicular tissue was used for biochemical and molecular analysis. To evaluate the pathological changes, hematoxylin and Eosin (H&E) staining were performed. The Malondialdehyde (MDA), Total antioxidant capacity (TAC), catalase (CAT) and Ferric-reducing antioxidant power (FRAP) levels were examined in order to evaluate the Reactive oxygen species (ROS) and antioxidant levels. Finally, Bax, Bcl-2, p53 and Caspase-3 mRNA levels were analyzed using real-time PCR.

**Result:** Our observations revealed that the MDA, Bax, p53 and caspase-3 level enhanced in the sole-SIM-received groups compared to control group, while level of TAC, catalase and Bcl-2 diminished in SIM-received groups versus control group. In contrast, Vitamin D-co-treated animals showed a significant enhancement in level of TAC, catalase and Bcl-2 compared to sole-SIM-received animals ( $p \leq 0.05$ ).

**Conclusion:** The vitamin D-co-administration can positively protect testicular tissue against SIM-induced oxidative stress condition by enhancing enzymatic activity of antioxidant defense and anti-apoptotic genes activation.

**Keywords:** Antioxidant, Apoptosis, Simvastatin, Stress oxidative, Vitamin D

### Introduction

World health organization (WHO) reports estimated that cardiovascular diseases (CVDs) such as coronary heart disease, cerebrovascular disease, rheumatic heart disease are the deadliest diseases globally and take nearly 17.9 million lives each year. Moreover, heart attacks and

**\*Corresponding Author: Najafi Tazekand Gholam Reza**, Department of Anatomy and Embryology, Faculty of Veterinary Medicine, Urmia University, Urmia, Iran  
Email: [g.najafi2006@yahoo.com](mailto:g.najafi2006@yahoo.com)  
<https://orcid.org/0000-0002-1085-6043>

strokes result in 4 out of 5 CVDs death cases and one third of these deaths occur prematurely in people under 70 years of age (1). Thus, using blood clotting depressors such as SIM plays an essential role in order to reduce CVDs mortality rate around the world (2). The SIM is a member of 3-hydroxy-3-methylglutaryl coenzyme A (HMG-CoA) reductase inhibitors (statins), known as preventers of CVDs. The statins reduce the CVDs risks not only by reducing cholesterol



levels, but also by stabilizing atherosclerotic plaque, improved endothelial function, enhanced fibrinolysis, and antithrombotic actions (3, 4). In line with this issue, it has been reported that the SIM has reduced the prothrombin activation rate, factor Va generation, fibrinogen cleavage, and factor XIII activation (2). Moreover, the SIM has been reported as an effective antioxidant and anti-inflammatory agent (5). Although, the SIM plays a key role in CVDs treatment, observation has revealed that the SIM results in various side effects such as muscle pain (6), myopathy (7), and testicular pain (8). Moreover, it has been shown that the SIM, by diminishing circulating cholesterol, impacts steroid hormones biosynthesis in testicular tissue (9). In addition, it has been reported that statins could fairly induce apoptosis by enhancing calcium amount in the cellular cytoplasm (10, 11). However, the precise mechanism of statins induced adverse effects has not been efficiently clear. Different mechanisms including membrane electrical potential disruption (12-14) inhibited CoQ10 (15,16) and disrupted biogenesis of mitochondria have been suggested. Accordingly, it has been clearly demonstrated that cholesterol is a potential anti-oxidant, which any reduction in cholesterol level and/or cholesterol deficiency results in cholesterol-induced oxidative stress in different tissues such as muscles (17). Moreover, reduced CoQ10 in statins administration condition leads to statins-induced oxidative stress due to essential anti-oxidant roles of CoQ10 (18). Regarding this issue, Sugiyamai and et al in 1980 showed that CoQ10 acts similar to  $\alpha$ -tocopherol in the heart mitochondria and inhibits oxidative stress (19). Additionally, CoQ10 is the only lipid-soluble antioxidant that cells can synthesize and the CoQ10 reduced form (Ubiquinol) is known as an important antioxidant against lipid-peroxidation (20). Thus, regarding statins disruptive effects on oxidative stress and anti-oxidant defense balance, it has been suggested that this mechanism might play an essential role in statins-induced side effects (18). Vitamin D (VD) is a well-known medicine in balancing the calcium and phosphorus homeostasis (21). However, VD acts as an essential element in maintaining endocrine hormones in both male and females (22, 23).

Apart from its general actions, it has been shown that VD is a potential anti-oxidant, which initiates the anti-oxidant related genes expression in animal models (24). In line with this issue, a recent conducted study has shown that reduced VD level results in testicular development disruption as well as spermatogenesis arrest due to inhibited germ cells proliferation (25). Moreover, VD deficiency has become a major concern during the last decade, especially VD deficiency in elderly people has been increased dramatically around the world (26, 27). Considering the adverse effects of statins that multi-pathologically impacts various organs including testicular tissue and based on VD positive impacts on these mechanisms in the current study we used VD in order to face the SIM negative effects on testicular tissue. Thus, we aimed to show the SIM possible adverse effects on testicular tissue oxidant balance and testosterone production using high and low doses of SIM. Additionally, we tried to show the VD protective effects potential against SIM-induced negative effects in testicular tissue. Moreover, in order to reveal the VD protective effects versus SIM-induced mitochondria-dependent apoptosis, we investigated Bax, Bcl-2 and p53 as well as caspase3 expression as a hall marker of mitochondria-dependent apoptosis.

## Materials & Methods

### Chemicals and materials

The simvastatin and vitamin D were purchased from Arya Pharmaceutical Company. The Primer for GAPDH (Sinacolon, Tehran, Iran), P53 (Sinacolon, Tehran, Iran), Caspase3 (Sinaclon, Tehran, Iran), BAX (Macrogene, Corea), Bcl-2 (Macrogene, Corea) were purchased from life-Teb-Gen Co., (Tehran, Iran). Testosterone assay using RTGC-768/98 kits. FRAP was evaluated using T-AOC Assay Kit (S0116, Beyotime, Shanghai, China). CAT levels were measured using biochemical assay kits (Navand Salamat, Urmia, Iran).

### Animals and Grouping

Forty-eight mature male Wistar rats (150-200 gr) were purchased from the animal house of



basic science faculty, Urmia University, Urmia, Iran. Based on the Laboratory Animal Care Ethics of Urmia University, a standard condition ( $23 \pm 2^\circ \text{C}$ , 12/12 day/night photoperiod and ad libitum food and water) were used in order to keep animals during the experiment. After 14 days of animals' adaptation period, animals were randomly categorized into control ( $n=8$  rats) and experimental groups ( $n=40$  rats). Then, animals in experimental group were subdivided into five equal groups ( $n=8$  rats in each group): (1) VD-received animals (VD-group, dose=  $5 \mu\text{L/kg}$ ), (2) low dose SIM-received animals (L.SIM-group, dose=  $0.5 \text{ mg/kg}$ ), (3) high dose SIM-received animals (H.SIM-group, dose=  $2 \text{ mg/kg}$ ), (4) low dose SIM-received animals and co-treated with VD (L.SIM+VD group), and (5) high dose SIM-received animals and co-treated with VD (H.SIM+VD group). It should be noted that the VD dose were administrated according to Hale et al study (28). Moreover, SIM administrated doses were based on Tunsophon and Chootip and ElBatsh conducted studies (29, 30).

### Testosterone Measurement

To measure of testosterone, after blood sampling, the serum was separated using a centrifuge ( $3000 \text{ g}$  for  $6 \text{ min}$ ) and kept at  $-70^\circ \text{C}$  until analysis of testosterone hormone. Serum testosterone concentrations were measured using an immunoradiometric technique using WHO/Sigma Asso-RTGC-768/98 kits (31).

### FRAP Measurement

The FRAP level of testicular tissue was evaluated based on the change in absorbance at  $593 \text{ nm}$  due to the formation of a blue-colored  $\text{Fe}^{2+}$ - tripyridyl triazine compound from colorless oxidized  $\text{Fe}^{3+}$  form through the activity of electron-donating antioxidants.

Working FRAP reagent was prepared by mixing  $25 \text{ ml}$  acetate buffer ( $\text{pH}=3.6$ ),  $2.5 \text{ mL}$  TPTZ (2,4,6-tripyridyl-s-triazine) in  $2.5 \text{ ml}$  ferric chloride ( $\text{FeCl}_3$ ) and  $40 \text{ mM}$  hydrochloride acid. Fifty  $\mu\text{L}$  of  $10\%$  homogenate was added to  $1.5 \text{ ml}$  freshly prepared reagent incubated at  $37^\circ \text{C}$ . After

$10 \text{ min}$ , the complex between  $\text{Fe}^{2+}$  and TPTZ gave a blue color.  $\text{FeSO}_4$  was used as a standard for FRAP assay and data were expressed as  $\text{mM/gr}$  of wet tissue. All solutions were used on the day of preparation (32).

### Measurement of Malondialdehyde (MDA) Level

MDA is the final product of fatty acid peroxidation, reacts with thiobarbituric acid (TBA) and produces a colored complex. The basis of spectrophotometric measurement of color is the reaction of TBA with MDA. In order to do this,  $300 \text{ microliters}$  trichloroacetic acid  $10\%$  was added to  $150 \text{ microliters}$  of sample and centrifuged at  $1000 \text{ rpm}$  for  $10 \text{ min}$  at  $4^\circ \text{C}$ . Three hundred microliters of supernatant were transferred to a test tube with  $300 \text{ microliters}$  of thiobarbituric acid  $67\%$  and incubated at  $100^\circ \text{C}$  for  $25 \text{ min}$ . Five min after cooling the solution, a pink color appeared because of MDA-TBA reaction and was evaluated using a spectrophotometer at a wavelength of  $535 \text{ nm}$  (33). MDA was expressed as micromolar of MDA/gr tissue (31).

### Measurement Catalase

To determine CAT levels  $0.5 \text{ gr}$  of testicular tissue homogenized in phosphate-buffered saline ( $0.1 \text{ mol/L}$ ,  $\text{pH}=7.4$ ) in cold condition to give  $10\%$  homogenate (w/v). The homogenates were centrifuged at  $10000 \text{ rpm}$  for  $10 \text{ min}$  at  $-4^\circ \text{C}$  and supernatant was processed for estimating CAT activity. The catalase (CAT) activity in homogenized testicular tissue was measured. The activity of CAT was based on the disappearance of hydrogen peroxide in the tissue homogenate ( $0.1 \text{ mL}$ ) of phosphate buffer ( $50 \text{ Mm}$ ;  $\text{pH}=7.0$ ) and  $2.9 \text{ mL}$   $\text{H}_2\text{O}_2$  in phosphate buffer ( $30 \text{ mM}$ ;  $\text{pH}=7.0$ ). The absorbance was read at  $240 \text{ nm}$  in a spectrophotometer (Pharmacia, Novaspec II, and Biochrom, England). Results were expressed as units/mg of tissue (34).

### Tissue Preparation and Histological Analyses

The testicular tissues were dissected out. The right testis was fixed in boean fixative solution, while the left testicular tissue was moved to



-80°C refrigerator for further biochemical and molecular experiments. Following 72 hours post fixation, the samples were routinely passaged and embedded in paraffin blocks. Next, the blocks were cut (5-6  $\mu$ m) using automatic rotary microtome and stained with Hematoxylin-Eosin (H&E) stain. Then, the stained slides were examined under a light microscope and Johnsen score (Table 1), tubular differentiation (TDI), and Spermiogenesis (SPI) indices as well as Leydig cells number per mm<sup>2</sup> were analyzed in 100 seminiferous tubules in each group (35).

### RNA Isolation and cDNA Synthesis

In order to isolate the stored testicles total RNA, TRIZOL method was used according to manufacture proved method (Sina-Gen, Tehran, Iran). Briefly, in the first step, the frozen tissues were homogenized using the TRIZOL reagent and chloroform (0.1 gr tissue were used). Then, homogenized samples were incubated on ice for 15 minutes, centrifuged in 12000 rpm for 10 minutes, and aqueous parts were placed into fresh micro tubes. In continuation, 500  $\mu$ L isopropanol solution was added to the mixtures, micro tubes were incubated on ice for 15 minutes, and centrifuged. Next, ethanol 70% was used in order to wash the removed supernatants. Finally, samples were air dried and 25  $\mu$ L DEPC-treated water was added. The concentration and efficiency of isolated RNAs content was

evaluated using nanodrop spectrophotometer (260 nm and A260/280=1.8-2.0).

In order to synthesize cDNA, a mixture containing RNA: Total RNA 10 ng~ 5 ug, mRNA 1 ng ~ 0.5 ug, Primer: Oligo (dT) 20:50 uM, Random Hexamer: 50 uM, Sequence-Specific Primer: 15~ 20 uM, 2X RTPre-Mix: 10  $\mu$ l, RNase-free Water was prepared and incubated for 5 min RT. The mixture was heated for 30 min at 50°C and RTase inactivation was performed for 5 mins at 95°C (BioFact, Corea).

### Real-Time PCR

The PCR reaction contained 0.5  $\mu$ L (about 5–10 ng) of cDNA template, 10  $\mu$ L 1X SYBR GREEN master mix (High ROX, BioFact, Corea), and 0.5  $\mu$ L (600 nM) from each reverse and forward primers of the target genes. PCR conditions were run as follows: general denaturation at 95 °C for 5 min, 1 cycle, followed by 45 cycles of 95 °C for 20 s; annealing temperature (61°C for GAPDH, 59°C for p53, 60°C for Caspase3, 60°C for Bax and 61°C for Bcl-2) for 10 s; elongation: 72 °C for 1 min and 72 °C for 5 min. The mean of triplicate target PCR threshold cycle (CT) values was normalized by subtracting the mean CT value of GAPDH. The relative expression level of interested mRNA was calculated by the equation:  $2^{-(Ct \text{ target} - Ct \text{ GAPDH})}$ . The primers pairs sequences for individual genes are presented in Table 1.

**Table1.** Oligonucleotide primers used for real - time RT-qPCR analysis

Target gene	Primer sequence 5'- 3'	length (bp)
Bax	GCCGAAATGTTTGCTGACG (Forward primer)	133
	CCGATCTCGAAGGAAGTCCA (Reverse primer)	
Caspase-3	GTTAACACGAGTGAGGATGTG (Forward primer)	136
	TACCCTGAAATGGCTTGTGT (Reverse primer)	
P53	GACTTCTTGTAGATGGCCATGG (Forward primer)	84
	ATGGAGGATTCACAGTCGGATA (Reverse primer)	





Bcl-2	ATCGCTCTGTGGTGACTGAGTAC (Forward primer) AGAGACAGCCAGGAGAAATCAAAC (Reverse primer)	118
GAPDH	AAGAAGGTGGTGAAGCAGGCATC (Forward primer) CGAAGGTGGAAGAGTGGGAGTTG (Reverse primer)	123

## Statistical Analyses

In the current study, all biochemical, histological and RT-PCR results are presented in Mean±SE. Differences between various groups were analyzed with one-way ANOVA, followed by Bonferroni test and a  $p \leq 0.05$  was considered statistically significant.

## Results

### Total body weight, testicular weight and TW/BW

Following 45 days, the total body weight, testicular weight as well as TW/BW ratio were examined. The results of the current study revealed that the total body weight post-treatment was not altered in intervened groups compared to the control group. Moreover, observation depicted that testicular weight reduced significantly in L.SIM and H.SIM groups compared to the control group ( $p \leq 0.05$ ). Meanwhile, VD-co-treatment significantly diminished SIM-induced negative effects on testicular weight in VD-treat groups versus the SIM-sole treated group ( $p \leq 0.05$ ). Evaluating TW/BW ratio illustrated a significant reduction in SIM-sole treated groups versus the control group, while VD-administration positively elevated the TW/BW ratio in VD-co-treated animals compared to SIM-sole received animals ( $p \leq 0.05$ ) (Table 2).

### Biochemical evaluation of Testicular tissue

To follow up testicular ROS content and anti-oxidant status, the MDA, Catalase, and Frap levels were examined. The biochemical assessment of testicular tissue illustrated enhanced MDA content level in SIM-sole groups in both low and high doses groups compared to the control group, while VD-co-treatment significantly reduced the level of MDA in

VD-received group versus SIM-sole groups ( $p \leq 0.05$ ). Additionally, CAT and Frap level in VD-administrated animals testicular tissue showed a remarkable enhancement compared to SIM low and high doses received animals (Table 2).

### Testosterone assessment

In L.SIM and H.SIM groups in comparison with con and VD groups, testosterone level reduced significantly ( $p \leq 0.05$ ) while VD in L.SIM+VD group remarkably increased testosterone levels in comparison with L.SIM and H.SIM groups ( $p \leq 0.05$ ) (Table 3).

### Histological analysis

The histological analysis illustrated that SIM-received animals showed remarkable pathological defects including cell dissociation, depilation, the disintegration of tubular basal membrane, and arrested spermatogenesis in their testicular tissue. Meanwhile, the VD-co-treated animals had fewer pathological defects, especially in the L.SIM group. In order to evaluate the testicular tissues changes more efficiently, positive TDI percentage, positive SPI percentage, and Leydig cell number per mm<sup>2</sup> were analyzed, respectively. Observation revealed that the histological parameters reduced significantly in SIM-sole treated animals versus the control group. However, VD-co-treatment could fairly ameliorate the negative impacts of H&E and result in enhanced histological parameters in the VD-received animals compared to SIM- sole treated groups. Moreover, our results indicated that the VD-co-treatment in SIM exposed animals could fairly improve histologically (Figure1 and Table 3).

# The bcl-2, bax, p53 and caspase-3 m RNA expression level examination

In order to evaluate the Bcl-2 mRNA expression the real-time PCR technique was used and the analysis was compared between groups. The observation revealed that the SIM administration remarkably diminished the Bcl-2 mRNA level versus the control group. On the other hand, the Bcl-2 mRNA level showed a significant increment in L.SIM+VD group animals versus SIM-sole received group animals ( $p \leq 0.05$ ), while there was no remarkable enhancement in H.SIM+VD group animals compared to SIM-administrated animals. The mRNA results illustrated that the Bax mRNA content significantly increased in SIM-sole received animals versus control animals ( $p \leq 0.05$ ). Moreover, the observation of data revealed that the Bax mRNA expression exhibited a mild reduction in VD-co-treated groups versus SIM-sole received groups. Meanwhile, there was an enhanced level of Bax mRNA expression in VD-sole received animals versus control group. The RT-PCR results represented

a remarkable increment in p53 mRNA level in SIM-sole received groups versus control group. No significant changes were observed between L.SIM and H.SIM groups. Accordingly, the mRNA level of p53 remarkably diminished in L.SIM+VD group animals versus SIM-sole received animals. Moreover, the p53 mRNA level diminished in H.SIM+VD group, while the results were not significant compared to SIM-sole received groups ( $p \leq 0.05$ ). The RT-PCR analysis illustrated a significant enhancement in caspase3 mRNA level in SIM-sole received groups versus control group ( $p \leq 0.05$ ). In addition, comparing two SIM-received groups with each other revealed remarkably higher level of caspase3 mRNA in H.SIM-received animals versus L.SIM-received group. Moreover, the mRNA level of caspase3 remarkably diminished in SIM+VD groups versus H.SIM-received animals, while there were no significant differences between L.SIM and H.SIM+VD groups. Simultaneously, the caspase-3 mRNA level diminished in L.SIM+VD group (Figure2 and Table 4).

**Table 2.** The effect of simvastatin and VD on body weight, Testicular weight, TW / BW, MDA, CAT and FRAP in different groups

Groups	Body weight (gr)	Testicular weight (gr)	TW / BW (mg)	MDA ( $\mu\text{mol}/\text{gr}$ tissue)	CAT (Units/mg tissue)	FRAP (mMg/gr tissue)
Control	185.81 $\pm$ 13.58 <sup>a</sup>	1.50 $\pm$ 0.07 <sup>a</sup>	8.07 $\pm$ 1.06 <sup>a</sup>	0.39 $\pm$ 0.02 <sup>a</sup>	0.59 $\pm$ 0.15 <sup>a</sup>	14.50 $\pm$ 0.52 <sup>a</sup>
VD 5 $\mu\text{l}/\text{Kg}$	185.36 $\pm$ 12.67 <sup>a</sup>	1.53 $\pm$ 0.07 <sup>a</sup>	8.25 $\pm$ 1.11 <sup>a</sup>	0.43 $\pm$ 0.02 <sup>ab</sup>	0.45 $\pm$ 0.14 <sup>a</sup>	12.97 $\pm$ 0.09 <sup>ab</sup>
L.SIM (0.5mg/Kg)	180.64 $\pm$ 10.61 <sup>a</sup>	1.09 $\pm$ 0.07 <sup>b</sup>	6.03 $\pm$ 0.99 <sup>b</sup>	0.55 $\pm$ 0.03 <sup>b</sup>	0.44 $\pm$ 0.05 <sup>b</sup>	12.36 $\pm$ 0.98 <sup>b</sup>
H.SIM (2mg/Kg)	180.27 $\pm$ 10.66 <sup>a</sup>	1.02 $\pm$ 0.06 <sup>b</sup>	5.65 $\pm$ 1.08 <sup>b</sup>	0.62 $\pm$ 0.04 <sup>b</sup>	0.39 $\pm$ 0.09 <sup>b</sup>	9.21 $\pm$ 0.03 <sup>c</sup>
L.SIM+ VD	183.62 $\pm$ 14.12 <sup>a</sup>	1.42 $\pm$ 0.08 <sup>a</sup>	7.73 $\pm$ 0.93 <sup>a</sup>	0.47 $\pm$ 0.3 <sup>b</sup>	0.52 $\pm$ 0.09 <sup>a</sup>	14.28 $\pm$ 0.08 <sup>a</sup>
H.SIM+ VD	183.71 $\pm$ 12.89 <sup>a</sup>	1.33 $\pm$ 0.08 <sup>a</sup>	7.23 $\pm$ 0.97 <sup>ab</sup>	0.58 $\pm$ 0.4 <sup>b</sup>	0.46 $\pm$ 0.13 <sup>a</sup>	11.45 $\pm$ 0.54 <sup>b</sup>

<sup>abc</sup> non-similar letters indicate a significant difference between groups in each column ( $p \leq 0.05$ ).

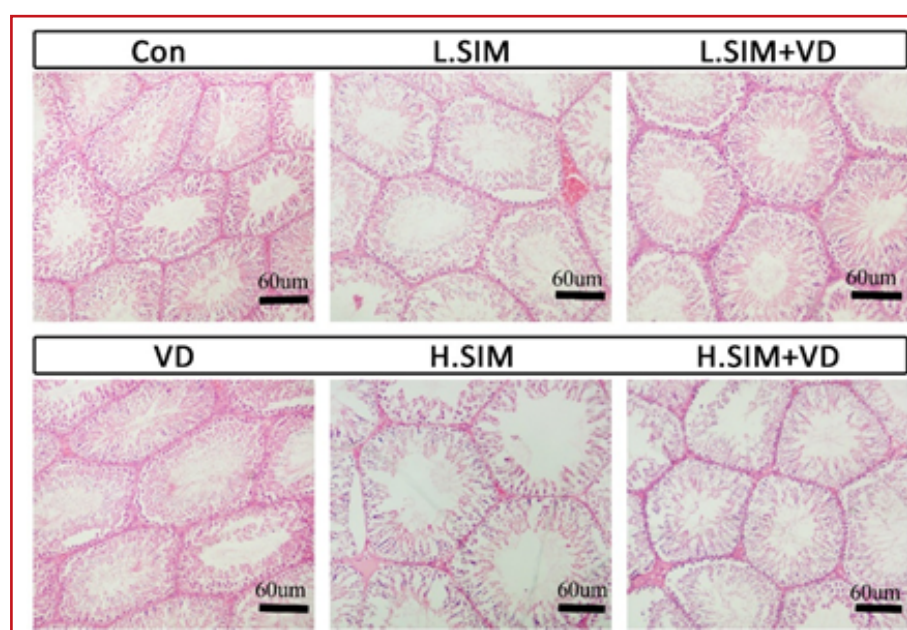
**Table 3.** The percentage of TDI and SPI positive, Leydig cells and serum level of testosterone in different groups

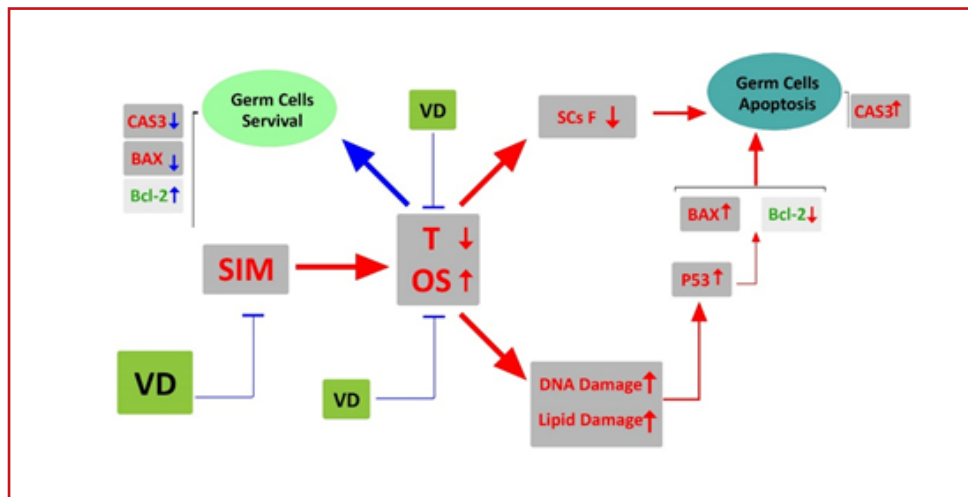
Groups	Positive TDI (%)	Positive SPI (%)	Leydig cell No/mm <sup>2</sup>	Testosterone (ng/ml)
Control	88.15±2.18 <sup>a</sup>	89.22±1.97 <sup>a</sup>	26.11±3/37 <sup>a</sup>	5.81±0.11 <sup>a</sup>
VD 5µl/Kg	86.85±1.94 <sup>a</sup>	91.03±2.66 <sup>a</sup>	23.08±2.89 <sup>a</sup>	5.73±0.23 <sup>a</sup>
L.SIM (0.5mg/Kg)	65.43±2.09 <sup>b</sup>	62.11± 2.18 <sup>b</sup>	18.76±2.14 <sup>a</sup>	5.59±0.28 <sup>b</sup>
H.SIM (2mg/Kg)	41.61±2.11 <sup>c</sup>	43.35±2.56 <sup>c</sup>	13.69±2/65 <sup>b</sup>	4.76±0.41 <sup>b</sup>
L.SIM+ VD	72.93±2.06 <sup>ab</sup>	74.05±2.37 <sup>b</sup>	21.97±1.70 <sup>a</sup>	5.74±0.32 <sup>a</sup>
H.SIM+ VD	59.07±1.98 <sup>b</sup>	59.42±2.41 <sup>b</sup>	14.09±2.52 <sup>b</sup>	5.66±0.28 <sup>b</sup>

<sup>abc</sup> non-similar letters indicate a significant difference between groups in each column ( $p \leq 0.05$ ).

**Table 4.** Real-time PCR results were analyzed and represented. Bcl-2, Bax, P53, and Caspase3 fold changes are represented in different groups

Groups	Bcl2	P53	Bax	Caspase 3
Control	0.98±0.21 <sup>a</sup>	0.99±0.43 <sup>a</sup>	0.94±0.51 <sup>a</sup>	1.01±0.28 <sup>a</sup>
VD 5µl/Kg	0.76±0.18 <sup>b</sup>	1.26±0.24 <sup>b</sup>	1.67±0.43 <sup>b</sup>	1.28±0.32 <sup>a</sup>
L.SIM (0.5mg/Kg)	0.53±0.20 <sup>c</sup>	1.60±0.19 <sup>b</sup>	2.48±0.54 <sup>c</sup>	1.84±0.28 <sup>b</sup>
H.SIM (2mg/Kg)	0.28±0.41 <sup>d</sup>	2.24±0.27 <sup>c</sup>	3.10±0.82 <sup>c</sup>	2.53±0.29 <sup>c</sup>
L.SIM+ VD	0.73±0.29 <sup>b</sup>	1.46±0.56 <sup>b</sup>	2.31±0.55 <sup>bc</sup>	0.87±0.37 <sup>a</sup>
H.SIM+ VD	0.31±0.32 <sup>d</sup>	1.81±0.35 <sup>b</sup>	2.98±0.42 <sup>c</sup>	1.68±0.21 <sup>b</sup>

<sup>abcd</sup> non-similar letters indicate a significant difference between groups in each column ( $p \leq 0.05$ ).

**Figure 1.** Micrographs presented in each group



**Figure 2.** A schematic figure representing the SIM administration pathophysiological effects in testicular tissue and VD protective effects against SIM-induced pathological effects

VD= vitamin D, T= testosterone, SIM=simvastatin, OS=oxidative stress

### Discussion

The aim of this investigation was to evaluate protective effect of VD on testicular histological alteration, ROS, and apoptotic gene expression in mice treated with low and high dose of simvastatin. The observation revealed that the SIM resulted in reduced TW and TW/BW rates compared to the control group. Moreover, MDA level examination illustrated that the SIM, by enhancing ROS, resulted in reduced catalase and frap level in testicular tissue, while VD-administration can positively enhance these enzymes levels in SIM-co-treated animals compared to sole SIM-received animals. Although, our histological results illustrated a significant reduction in TDI, SPI, and Leydig cell number per mm<sup>2</sup> in SIM-received animals versus control group, VD-co-treated animals showed remarkable enhancement in testicular parameters compared to SIM-sole groups. Meanwhile, the serum level of testosterone enhanced in VD-administrated animals versus sole SIM-received animals. Finally, our RT-PCR results confirmed the VD-co-treatment positive protective effects against SIM-induced negative impacts on testicular tissue by enhancing Bcl-2 and diminishing Bax, P53, and Caspase3 mRNA expression.

Accordingly, a significant reduction of MDA

(presents massive lipid peroxidation) and remarkably diminished catalase and Frap level (representing ROS impact on enzymatic antioxidant defense of testicular tissue) were revealed in non-treated SIM-received animals' testicular tissues. However, the animals in VD-treated groups showed diminished MDA contents and improved TAC and Frap level versus non-treated SIM-administrated groups. These results could be ascribable to the high amount of polyunsaturated fatty acids (PUFA) in the architecture of germinal cells in testicular tissue, which describes the male germ cells' high susceptibility to lipid peroxidation.

Minding the cholesterol antioxidant potential (36, 37) the SIM by reducing circulating cholesterol (38), leads to massive oxidative stress in the testicular tissue. Moreover, it has been revealed that the SIM inhibits the CoQ10 and disturbs the mitochondria membrane electrical potential balance (14, 15). Given the mitochondria highlighted role in ROS production (36), any disruption in mitochondria membrane balance could lead to massive ROS release from mitochondria and result in enormous oxidative stress in the testicular tissue (39). On the other hand, our observation illustrated that the VD-co-treated animals exhibited diminished MDA level in testicular tissue, while catalase and frap level





enhanced versus SIM-sole-received animals. Based on VD antioxidant potential role (25), we can hypothesis that VD administration could positively inhibit the ROS activity in the testicular tissue facing SIM-induced oxidative stress.

Observation revealed that the SIM administration significantly diminished the Leydig cells number per mm<sup>2</sup> in non-treated SIM-received groups versus the control group. Moreover, the serum level of testosterone showed a remarkable reduction in non-treated SIM-received animals compared to the control group. On the other hand, VD-co-treated animals revealed a remarkable enhancement in Leydig cell number per mm<sup>2</sup> and serum level of testosterone versus non-treated SIM-received animals. To understand these findings, it should be noted that testosterone plays a key role in cross-network between testicular endocrine status and spermatogenesis. In line with the current issue, it has been revealed that testosterone affects Sertoli cells function by their androgen receptors mechanism (40) as well as by enhancing their intracellular Ca<sup>2+</sup> level (41). Moreover, testosterone promotes gene transcription in Sertoli (42) and spermatogonia cells (43). In line with this issue, it is well known that the Sertoli cells are the germ cells nurse cells, which provide the germ cells energy fuel as well as their essential role in secreting growth factors for promoting germ cells divisions such as GDNF (44). Additionally, it has been revealed that testosterone directly impacts germ cells division especially as stage VII seminiferous tubules (45, 46). Taking together, the serum level of testosterone is an important reflector of normal spermatogenesis in different spermatogenesis cycles in testicular tissue. Considering all aforementioned we tried to evaluate the testicular endocrine estate by assessing the serum level of testosterone. Thus, similar to a previously conducted study by Azzarito et al, the SIM-received animals illustrated significantly reduced testosterone in serum, while treatment with VD could remarkably enhance the testosterone level (47). Meanwhile, the serum

level of testosterone up-regulation in VD-treated animals reflects the ameliorative effect of VD on the endocrine status and resulted in improved histological parameters in these groups. Therefore, our results in coordination with previous studies reveal that the VD key role in endocrine hormones maintaining and balance in testicular tissue (22, 23).

Based on previously conducted studies, it has been revealed that in the oxidative stress situation, the mitochondria membrane electron transport chain generates ROS such as superoxide radicals on the cellular scale (48, 49). Indeed, mitochondria are known as an important organelle with ROS-generating potential, which becomes a ROS-target organelle in oxidative stress conditions (50, 51). In line with this issue, Bcl-2 family proteins play an essential role to maintain mitochondria membrane permeability facing oxidative stress conditions (52). However, under stress conditions and in the absence or reduction of Bcl-2, the Bax oligomerization occurs and facilitates the cytochrome c release into the cytoplasm (53). Thus, the cytochrome c, in turn, initiates various genes expression leading to caspase-3 over-activation. The caspase-3, as finisher protein, cleaves the DNA and protein-made structures (54, 55) resulting in apoptosis. On the other hand, it has been revealed that the p53 as a DNA guardian gene in the ROS-induced DNA damage condition, activates in order to trigger the DNA repairmen and/or p53-dependent apoptosis (56). It should be noted that the p53 induces Bax overexpression and oligomerization in ROS-induced massive DNA damage in order to initiate mitochondria-dependent apoptosis (57, 58). Minding diminished expressions of p53, Bax, and Caspase3 in the VD-co-treated groups and considering roles of these three proteins in apoptosis, we can come close to the fact that VD plays an important role in synchronizing those proteins involvement in SIM-induced apoptosis processes. Moreover, mRNA results of Bcl-2 exhibited the VD-induced positive effects in remarkably up-regulating this protein expression level in VD-co-treated animals versus non-treated SIM-received animals.



## Conclusion

Our findings showed that vitamin D is able to protect the testicular tissue against SIM-induced testicular dysfunction via enhancing serum level of testosterone, up-regulating enzymatic defense of antioxidant potential of testicular tissue. Moreover, we showed that vitamin D is able to maintain Bcl-2 and down-regulating Bax and caspase-3 expression, in SIM-induced intrinsic apoptosis pathway conditions. Thus, taking together, vitamin D exerts an anti-apoptotic effect and is able to boost spermatogenesis by enhancing endocrine status (Note Figure 4). compared to the L.SIM group.

## Acknowledgement

The authors gratefully acknowledge the kind cooperation of all staff in the department of basic science, faculty of veterinary medicine, Urmia University in conducting this study. This article was part of an MSc thesis and its ethics identifier is IR.UU.AEC.2020.

## Conflict of Interest

The authors declare that there is no conflict of interest that would prejudice the impartiality of this study.

## References

- Mehra M, Desai S, Kuy S, Henry T, Patel A.. Retraction: Cardiovascular Disease, Drug Therapy, and Mortality in Covid-19 . N Engl J Med. 2020;382:1-7.
- Undas A, Brummel K, Musial J, Mann K Szczeklik A. Simvastatin depresses blood clotting by inhibiting activation of prothrombin, factor V, and factor XIII and by enhancing factor Va inactivation. Circulation. 2001;103: 2248-53.
- LaRosa J, He J, Vupputuri S.. Effect of statins on risk of coronary disease: a meta-analysis of randomized controlled trials. Jama. 1999; 282: 2340-46.
- Maron D, Fazio S, Linton M. Current perspectives on statins. Circulation. 2000; 01: 207-213.
- Shalizar Jalali A, Behfar M, Najafi G, Nourian A, Shahkarimi M, Koohestani M. The suppressive effects of Simvastatin on fertility impairment induced by experimental unilateral testicular ischemia-reperfusion in mice. Caspian J Reprod Med. 2016; 2: 10-14.
- Bruckert E, Hayem G, Dejager S, Yau C, Bégaud B.. Mild to moderate muscular symptoms with high-dosage statin therapy in hyperlipidemic patients—the PRIMO study. Cardiovasc Drugs Ther. 2005; 19: 403-14.
- Hu M, Mak V, Tomlinson B. Intronic variants in SLC01B1 related to statin-induced myopathy are associated with the low-density lipoprotein cholesterol response to statins in Chinese patients with hyperlipidaemia. Pharmacogenet. Genomics. 2012; 22: 803-6.
- Linnebur S, Hiatt W. Probable statin-induced testicular pain. Ann Pharmacother. 2007; 41: 138- 42.
- Dobs A, Miller S, Neri G, Weiss S, Tate A, Shapiro D, et al. Effects of simvastatin and pravastatin on gonadal function in male hypercholesterolemic patients. Metabolism . 2000; 49: 115- 21.
- Dirks A, Jones K. Statin-induced apoptosis and skeletal myopathy. Am J Physiol Cell Physiol. 2006; 291: 1208- 12.
- Sirvent P, Mercier J, Lacampagne A. New insights into mechanisms of statin-associated myotoxicity. Curr Opin Pharmacol. 2008; 8: 333- 38.
- Rosenson R. Current overview of statin-induced myopathy. Am. J. Med. 2004; 116: 408- 16.
- Shrivastava A, Khan A, Jain S, Singhal P, Jain S, Marotta F, et al.. Biotechnological advancement in isolation of anti-neoplastic compounds from natural origin: a novel source of L-asparaginase. Acta Biomed. 2010; 81: 104- 8.
- Thompson P, Clarkson P, Karas R. Statin-associated myopathy. Jama. 2003; 289: 1681-90.
- Kalra S. The role of Coenzyme Q10 in statin-associated myopathy. Electron Physician. 2009 ;1: 2-8.
- Marcoff L, Thompson P. The role of coenzyme Q10 in statin-associated myopathy: a systematic review. J Am Coll Cardiol. 2007; 49: 2231- 37.
- Smith L. Another cholesterol hypothesis: cholesterol as antioxidant. Free Radic Biol Med. 1991; 11: 47-61.
- Ahmadi Y, Ghorbanihaghjo A, Naghizadeh M, Yagin N. Oxidative stress as a possible mechanism of statin-induced myopathy. Inflammopharmacology. 2018; 26: 667- 74.
- Sugiyama S, Kitazawa M, Ozawa T, Suzuki K, Izawa Y. Protective effect of Coenzyme Q 10 against carbon tetrachloride-induced liver injury. Nagoya J. Med. Sci. 1980; 43: 25- 27.
- Littarru G, Tiano L. Bioenergetic and antioxidant properties of coenzyme Q 10: recent developments. Mol. Biotechnol 2007; 37: 31- 37.
- Duchow E, Cooke N, Seeman J, Plum L, DeLuca H. Vitamin D binding protein is required to utilize skin-generated vitamin D. Proceedings of the National Academy of Sciences 2019; 116:24527- 32.
- Jensen B, Nielsen J, Axelsson M, Pedersen M, Löfman C, Wang T. How the python heart separates pulmonary and systemic blood pressures and blood flows. Journal of Experimental Biology. 2010; 213: 1611- 17.
- Shahrokhi S, Ghaffari F, Kazerooni F. Role of vitamin D in female reproduction. Clinica chimica acta. 2016; 455: 33-8.
- Cao R, Zhang Y. SUZ12 is required for both the histone methyltransferase activity and the silencing function of the EED-EZH2 complex. Molecular cell. 2004; 15: 57-7.
- Fu L, Chen Y-H, Xu S, Ji Y-L, Zhang C, Wang H,



- Ahmadi Y, Ghorbanihaghjo A, Naghizadeh M, Yagin N. Oxidative stress as a possible mechanism of statin-induced myopathy. *Inflammopharmacology*. 2018; 26: 667- 74.
19. Sugiyama S, Kitazawa M, Ozawa T, Suzuki K, Izawa Y. Protective effect of Coenzyme Q 10 against carbon tetrachloride-induced liver injury. *Nagoya J. Med. Sci.* 1980; 43: 25- 27.
20. Littarru G, Tiano L. Bioenergetic and antioxidant properties of coenzyme Q 10: recent developments. *Mol. Biotechnol* 2007; 37: 31- 37.
21. Duchow E, Cooke N, Seeman J, Plum L, DeLuca H. Vitamin D binding protein is required to utilize skin-generated vitamin D. *Proceedings of the National Academy of Sciences* 2019; 116:24527- 32.
22. Jensen B, Nielsen J, Axelsson M, Pedersen M, Löfman C, Wang T. How the python heart separates pulmonary and systemic blood pressures and blood flows. *Journal of Experimental Biology*. 2010; 213: 1611- 17.
23. Shahrokhi S, Ghaffari F, Kazerouni F. Role of vitamin D in female reproduction. *Clinica chimica acta*. 2016; 455: 33-8.
24. Cao R, Zhang Y. SUZ12 is required for both the histone methyltransferase activity and the silencing function of the EED-EZH2 complex. *Molecular cell*. 2004; 15: 57-7.
25. Fu L, Chen Y-H, Xu S, Ji Y-L, Zhang C, Wang H, Yu D-X, Xu D-X. Vitamin D deficiency impairs testicular development and spermatogenesis in mice. *Reprod Toxicol*. 2017; 73: 241-49.
26. Holick M. Vitamin D deficiency. *N Engl J Med*. 2007; 357: 266-81.
27. Sahota O. Understanding vitamin D deficiency. *Age and ageing*. 2014; 43: 589.
28. Hale L, Craver K, Berrier A, Sheffield M, Case L, Owen J. Combination of fosinopril and pravastatin decreases platelet response to thrombin receptor agonist in monkeys. *Arterioscler Thromb Vasc Biol*. 1998; 18: 1643-46.
29. ElBatsh M. Antidepressant-like effect of simvastatin in diabetic rats. *Can J Physiol Pharmacol*. 2015; 93: 649-56.
30. Tunsophon S, Chootip K. Comparative effects of piperine and simvastatin in fat accumulation and antioxidative status in high fat-induced hyperlipidemic rats. *Can J Physiol Pharmacol*. 2016; 94: 1344-48.
31. Ensieh Z, Gholamreza N, Vahid N, Reza H. Protective effect of royal jelly on the sperm parameters and testosterone level and lipid peroxidation in adult mice treated with oxymetholone. *Avicenna J Phytomed*. 2014; 4: 43-2.
32. Katalinic V, Modun D, Music I, Boban M. Gender differences in antioxidant capacity of rat tissues determined by 2, 2'-azinobis (3-ethylbenzothiazoline 6-sulfonate; ABTS) and ferric reducing antioxidant power (FRAP) assays. *Comparative Biochemistry and Physiology Part C: Pharmacol Toxicol*. 2005; 140: 47-2.
33. Hosseinzadeh H, sadeghnia R. Safranal, a constituent of *corcussativus*, attenuated cerebral ischemia induced oxidative damage in rat hippocampus .*pharm pharmaceut*. 2005; 8; 394-99.
34. Akondi R, Kumar P, Annapurna A, & Pujari M. Protective effect of rutin and naringin on sperm quality in streptozotocin (STZ) induced type 1 diabetic rats. *Iran J Pharm Res*. 2011; 10: 585.
35. Minas A, Najafi G, Jalali A.S, Razi M. Fennel induces cytotoxic effects against testicular germ cells in mice; evidences for suppressed pre-implantation embryo development. *Environ. Toxicol*. 2018; 33: 841-50.
36. Khavarimehr M, Nejati V, Razi M, Najafi G. Ameliorative effect of omega-3 on spermatogenesis, testicular antioxidant status and preimplantation embryo development in streptozotocin-induced diabetes in rats. *Int Urol Nephrol*. 2018; 49; 1545-60.
37. Chapman M, Le Goff W, Guerin M, Kontush A. Cholesteryl ester transfer protein: at the heart of the action of lipid-modulating therapy with statins, fibrates, niacin, and cholesteryl ester transfer protein inhibitors. *Eur Heart J*. 2010; 31: 149-64.
38. Fraunberger P, Gröne E, Gröne H, Walli A. Simvastatin reduces endotoxin-induced nuclear factor  $\kappa$ B activation and mortality in guinea pigs despite lowering circulating low-density lipoprotein cholesterol. *Shock*. 2009; 32: 159-63.
39. Shamsi-Gamchi N, Razi M, Behfar M. Testicular torsion and reperfusion: evidences for biochemical and molecular alterations. *Cell Stress Chaperones*. 2018; 23: 429-39.
40. Smith L, Walker W. The regulation of spermatogenesis by androgens, *Seminars in cell & developmental biology*. Elsevier. 2014; pp: 2-13.
41. Walker W, Cheng J. FSH and testosterone signaling in Sertoli cells. *Reproduction*. 2055; 130: 15-28.
42. Cheng J, Watkins S, Walker W. Testosterone activates mitogen-activated protein kinase via Src kinase and the epidermal growth factor receptor in sertoli cells. *Endocrinology*. 2007; 148: 2066-74.
43. Lord T, Nixon B. Metabolic Changes Accompanying Spermatogonial Stem Cell Differentiation. *Dev. Cell* . 2020; 52: 399-411.
44. Rashtbari H, Razi M, Hassani-Bafrani H, Najaran H. Berberine reinforces Sertoli cells niche and accelerates spermatogonial stem cells renewal in experimentally-induced varicocele condition in rats. *Phytomedicine*. 2018;40: 68-78.
45. Holdcraft R, Braun R. Androgen receptor function is required in Sertoli cells for the terminal differentiation of haploid spermatids. *Development*. 2004; 131: 459-67.
46. Pierik F, Stijnen T, de Jong F, Weber R, Vreeburg J. Serum inhibin B as a marker of spermatogenesis. *J Clin Endocrinol Metab*. 1998; 83: 3110-14.
47. Azzarito C, Boiardi L, Vergoni W, Zini M, Portioli I. Testicular function in hypercholesterolemic male patients during prolonged simvastatin treatment. *Horm. Metab. Res*. 1996; 28: 193-98.
48. Circu M, Moyer M, Harrison L, Aw T. Contribution of glutathione status to oxidant-induced mitochondrial DNA damage in colonic epithelial cells. *Radic Biol Med*. 2009;



- 47: 1190-98.
49. Orrenius S, Gogvadze V, Zhivotovsky B. Mitochondrial oxidative stress: implications for cell death. *Annu. Rev. Pharmacol. Toxicol.* 2007; 47: 143-83.
50. Rachek L, Yuzefovych L, LeDoux S, Julie N, Wilson G. Troglitazone, but not rosiglitazone, damages mitochondrial DNA and induces mitochondrial dysfunction and cell death in human hepatocytes. *Toxicol. Appl. Pharmacol.* 2009; 240: 348-54.
51. Sinha B, Kumar A, Bhattacharjee S, Espey M, Mason R. Effect of nitric oxide on the anticancer activity of the topoisomerase-active drugs etoposide and adriamycin in human melanoma cells. *J Pharmacol Exp Ther.* 2013; 347: 607-14.
52. Lindsay J, Degli Esposti M, Gilmore A. Bcl-2 proteins and mitochondria—specificity in membrane targeting for death. *Biochim Biophys Acta.* 2011; 1813: 532-39.
53. Mosadegh M, Hasanzadeh S, Razi M. Nicotine-induced damages in testicular tissue of rats; evidences for bcl-2, p53 and caspase-3 expression. *J Basic Med Sci.* 2017; 20: 199.
54. Brentnall M, Rodriguez-Menocal L, De Guevara R, Cepero E, Boise L. Caspase-9, caspase-3 and caspase-7 have distinct roles during intrinsic apoptosis. *BMC Cell Biol.* 2013; 14: 32.
55. Zamir-Nasta T, Razi M, Shapour H, Malekinejad H. Roles of p21, p53, cyclin D1, CDK-4, estrogen receptor  $\alpha$  in aflatoxin B1 induced cytotoxicity in testicular tissue of mice. *Environ. Toxicol.* 2018; 33: 385-95.
56. Yasin M, Mazdak R, Mino I. Aflatoxin B1 impairs spermatogenesis: An experimental study for crosslink between oxidative stress and mitochondria-dependent apoptosis. *Environ. Toxicol* 2018; 33: 1204-13.
57. Amaral J, Xavier J, Steer C, Rodrigues C. The role of p53 in apoptosis. *Discov Med Discov Med.* 2010; 9: 145-52.
58. Nowsheen S, Yang E. The intersection between DNA damage response and cell death pathways. *Exp. Oncol.* 2012; 34: 243.