



The Report of a Surgical Residual Largas Inside the Renal Pelvis 16 Years after Surgery “Case Report”

Ashrafi Mojtaba^{1*}, Afsharimoghadam Amin², Rezaie Keikhaie Khadije³, Kamali Atefeh⁴

1. Department of Urolog, Faculty of Medicine, Zahedan University of Medical Sciences, Zahedan, Iran

2. Department of Surgery, Faculty of Medicine, Amir al-Momenin Hospital, Zabol University of Medical Sciences, Zabol, Iran

3. Zabol Medicinal Plants Research Center, Zabol University of Medical Sciences, Zabol, Iran

4. Student Research Committee, Zabol University of Medical Sciences, Zabol, Iran

Received: 28 Apr 2022 Accepted: 16 Jul 2022

Abstract

Background & Objective: Gossypiboma is the meaning of a residual foreign body such as gas in the abdomen following surgical operation, which is a rare complication of surgery. Residual of a foreign body causes mass, fistula, abscess and, obstruction after surgical operation. Computed tomography (CT) scan is a very useful method in the diagnosis of Gossypiboma. In patients who referred with abdominal pain and unexplained manifestations after surgery, Gossypiboma should be considered.

Case presentation: A retrospective case study was performed in the year 2020 in a patient with a history of open kidney stone surgery in Hospital of Zabol. A 60-year-old male patient who referred with complaint of neck pain to an orthopedic doctor, which due to a history of kidney stone, the doctor orders an ultrasound of the kidneys. In the ultrasound, a number of stones are observed in the right kidney of this patient. After performing CT scan and Intravenous pyelography (IVP), a foreign body is identified inside the renal pelvis. In the following, the history taken from the patient, the history of open kidney stone surgery during 16 years ago in this patient is determined. During this period, the patient did not have any symptoms, including infection or pain in the mentioned area.

Conclusion: In patients with a history of surgery who are referred with abdominal pain or mass, the residual foreign body should be included in the list of differential diagnoses.

Keywords: Gossypiboma, Holder surgical sponges, Kidney stone

Introduction

Gossypiboma is a Latin word meaning the concealment of cotton or cotton cloth (1, 2). It indicates the presence of a cotton or cloth mass following surgery, which can cause many medical problems for the patient and legal problems for the surgeon (3).

***Corresponding Author: Ashrafi Mojtaba**, Department of Urolog, Faculty of Medicine, Zahedan University of Medical Sciences, Zahedan, Iran
Email: mojtaba.ashrafi94@gmail.com
<https://orcid.org/0000-0003-2572-8404>

A wide range of residual surgical objects have been reported, including instruments such as clamps and sutures, but surgical sponges are probably the most common object due to their amorphous composition and frequent use (4).

Often with emergency measures, the long term surgeries, unexpected changes during the process of the surgery operation, excessive bleeding, change of personnel during the surgery operation or a number of inexperienced and inadequate staff may occur (5).

Gossypiboma may lead to the chronic abdominal pain, abdominal mass, intestinal obstruction, hidden infections, and fistula and as a result of the migration of foreign body into the small and large intestine or stomach (6, 7). The incidence of this error is 1 in every 1000 to 1500 laparotomy (8). However, this figure is not detected in different countries and areas and depends on economic and social conditions and the progress rate of the health system (9). Gossypiboma is a low-development area that could be due to advanced operating rooms and operating room techniques. There is also no more accurate information and statistics numerically. Although Gossypiboma may be detected in different parts, according to the study of Van et al., it is found in the body especially in the abdomen (56%), pelvis (18%) and chest (11%)(9, 10). Gossypiboma in the abdominal cavity leads to two responses: the exudative response that leads to the formation of abscesses (8) and the second type of response is non-septic form which is accompanied by the formation of adhesion and capsule around a foreign body and may remain for many years (10, 11). The pathological process caused by Gossypiboma initially results in a granulomatous reaction around the sponge which creates exudate and the formation of abscesses and phlegmon, and eventually fibrosis. Many of these patients are completely asymptomatic at first and may take symptoms from a few days to as long as 28 years. According to the proliferation of minimally invasive surgeries as well as the use of radiopaque pads and the improvement of preoperative protocols including gases recouping and the use of X-RAY in suspected cases, this statistic is declining (12). Due to the fear of the doctor, legal concepts, public criticism of the medical profession, there is a refusal to publish this article (13). Gossypiboma can be used to count sponges before and after surgery, use of radiant sponges with radiation indicators, labeling sponges, and compresses used in the abdomen, and adequate field and radiographic examination of the abdomen, if necessary, before the wound is closed (13-15).

The objective of this study was to report a case with 1 sterile gas remaining in the kidney.

Case presentation

A retrospective case study was performed in the year 2020 in a patient with a history of open kidney stone surgery in Hospital of Zahedan. A 60-year-old male patient who referred with complaint of neck pain to an orthopedic doctor, which due to a history of kidney stone, the doctor orders an ultrasound of the kidneys. In the ultrasound, a number of stones is observed in the right kidney of this patient and then this patient referred to an urologist for the course path of treatment, after performing a CT scan and IVP, the presence of a foreign body inside the pelvis of the kidney is determined. In the following the history taken from the patient, the history of open kidney stone surgery during 16 years ago in this patient is determined. During this period, the patient did not have any symptoms, including infection or pain in the mentioned area.

Results

In an abdominal ultrasound was performed on the patient's kidney, and it was observed that a 15 mm stone in the upper calyx, a 11 mm stone in the middle calyx, a 13 mm in the lower calyx, and several other small stones were observed in the form of scattering in the right kidney. Also, a foreign body was seen in the area (inside the kidney pelvis) of diffuse calcification in the right kidney, which suggested for further CT scan examination. Intravenous pyelogram (IVP) showed that the right kidney is secreting a contrast agent, as a result, it was found that kidney function was normal, and all efforts were made to preserve the kidney (Figure 1A).

The patient underwent a CT scan with contrast-free oral and intravenous without contrast material which was similar to a round, leaf-like mass with the dimensions of 4 x 8 cm and was seen as cystic (Figure 1B).

A laparotomy was performed in the same area of the previous surgery but with a smaller incision (Fig. 1C), and the pelvic region of the right

kidney was examined as it was removed from the patient's right kidney for 16 years (Fig. 1D).

The nature of the mass was not known before the surgery operation. The other

kidney organs were normal and did not have any pathology. The patient was discharged from the surgical service after a few days in good general condition.

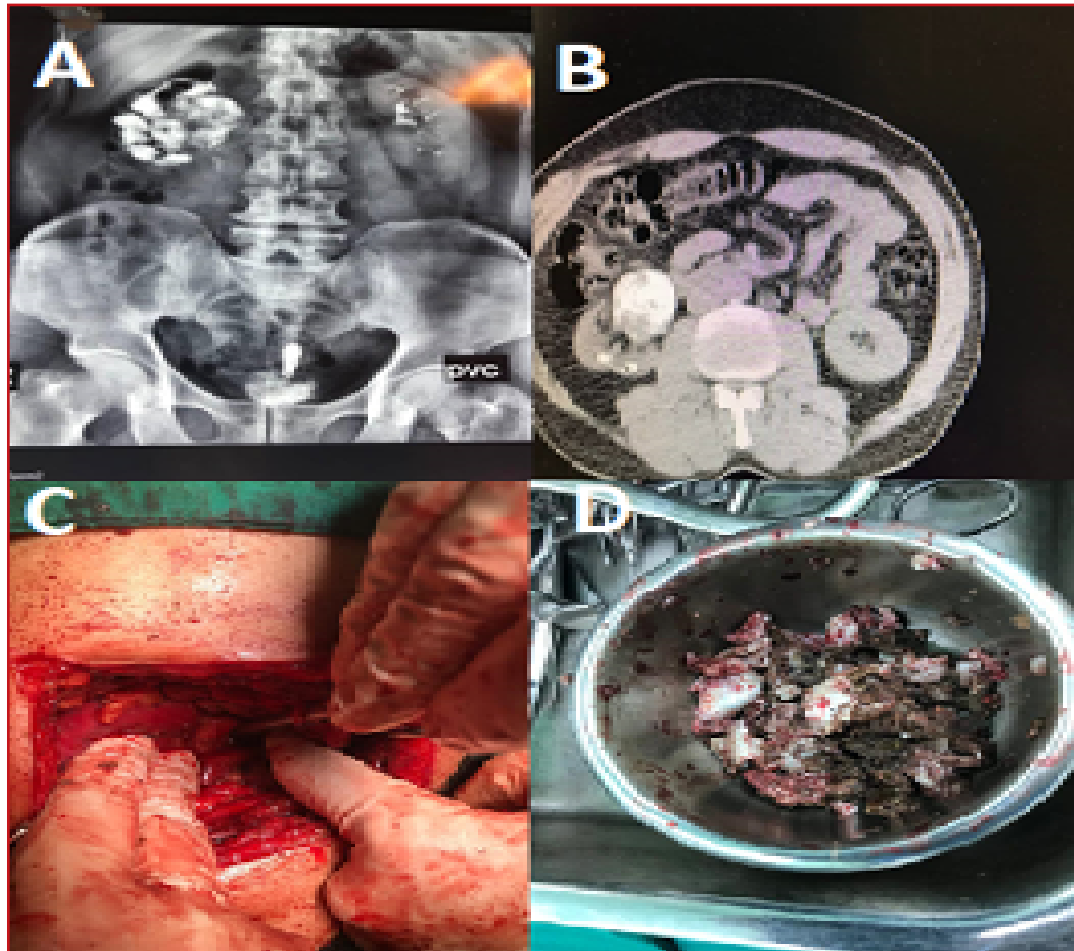


Figure 1. (IVP) shows the presence of a foreign body in the kidney secreting a contrast agent (A). (CT) scan of the patient shows a contrasting foreign body in a cystic space (B). The gap created for the removal of a foreign object (C). A foreign object (band) removed from the right kidney (D).

Discussion

The incidence of residual surgical sponge (RSS) is difficult to estimate because some patients remain asymptomatic and never detected, and due to the lack of records of some diagnosed cases. However, the reported incidence varies between 1/1,00 and 3,000 procedures (16).

Gossypiboma is the most common foreign body residual in the body following the surgery completion and should be placed on the list of differential diagnoses due to abdominal pain and infection after surgery (17). Clinical manifestation and as well as timing of symptoms

of this complication is very different, so that 50% of cases have been reported asymptomatic and in some cases with acute or chronic symptoms (18, 19). The incidence of Gossypiboma is not only due to the legal consequences of its findings, but also it is less reported because many patients remain asymptomatic. However, if we are supposed to give a number, 1/1000 to 1/1500 cases can occur in intra-abdominal surgery operations. Clinical manifestations are variable and depend on the location of the foreign body and the type of body reaction (20).

The rate of Gossypiboma is low in developed countries, which can be due to the operating room and advanced radiology techniques (3). If foreign objects are radiopaque, they can be detected even in simple graphics. Cotton foreign objects such as towels or sponges are seen on CT scan in the form of a round mass with a central density and a contrast wall and other features of a sponge include whorl-like with air bubbles inside it or cystic masses (21).

Once the cotton material remains in the abdominal cavity, one of the two processes is guaranteed. If the material is contaminated, pyogenic granulomas are created. The formed abscess eventually ruptures into a hollow viscosity and then the pus is secreting and then bleeding and the removal of a foreign body is performed. If the foreign body cannot be extruded, it remains in the abscess cavity and causes to create multiple fistulas. In such a case, when the patient is recovering well after surgery, he/she becomes chronically ill and complains from vague abdominal symptoms (21, 22). The diagnosis time varies from 6 hours to 40 years after surgery, so this situation in some cases is diagnosed completely accidental (23). Diagnostic features have been discussed in a variety of imaging methods including radiography, examination with contrast material, ultrasonography, and CT scan (24).

Wilson reported the first case of Gossypiboma in 1884. From the beginning of the twentieth century, the use of radiopaque sponges has been recommended to prevent cases of Gossypiboma (25).

In a case reported by Celik et al., in 2021, a 36-year-old female patient referred with severe abdominal pain and distention, after the examination it was found that about 7 years ago, after an ectopic pregnancy and abdominal radiography obtained from a soft tissue mass in the center of the abdomen (Gossypiboma), she underwent surgery (26). In a case reported by Bozkırlı et al., in 2020, a 34-year-old male patient was admitted to our clinic for complaint due to post-meal nausea and vomiting and abdominal

distension that was evident for the past 5 months. He had a history of Nissen fundoplication for the past 10 years, which was performed with the open method. A large mass was palpable in the epigastrium and both the upper and lower left quadrants of the abdomen. Computed tomography (CT) of the abdomen showed a 20 × 18 cm calcified cystic mass with a sprouted membrane inside it.

Although the indirect hemagglutination test was negative, the patient underwent surgery with a suggested diagnosis of type 3 hydatid cysts. Laparotomy showed a large mass that filled the epigastrium and then this mass spread to both the upper and lower left quadrants of the abdomen. It was impossible to dissect the false capsule of the mass from adjacent structures. When the false capsule was opened, 3 liters of odorless brown-black liquid came out. In the cystic cavity, there was a 30 × 30 cm abdominal compress near the esophageal hiatus, after that the compress was extracted and then the cavity was washed with saline. After inserting the drain into the cavity, the abdomen was closed. The patient was discharged from the hospital on the second day after surgery without any problems (27). In a case reported by Berhanu et al., in 2019, a 32-year-old female patient referred with severe abdominal pain and intestinal distention about 4 months before giving birth, after the abdominal examination it was found that a surgical sponge has remained in the rectum that again underwent surgery (2).

In a case reported by Gilbert Maranya in 2018, an 18-year-old male patient who had undergone pelvic surgery 12 years before, it was reported that the patient referred to the hospital with fever, right hydronephrosis, bilateral kidney stones, and contracted bladder (28), he underwent the sponge removal surgery and the bladder release (29).

Early diagnosis of Gossypiboma and following it, immediate surgical recovery usually leads to an excellent prognosis. In case of late diagnosis, complications and mortality rate increase significantly because often in these conditions, major surgery operations are required (30).

Conclusions

The importance of reported case in this article is that sometimes Gossypiboma can remain silent and suddenly indicates its manifestation. Preventing Gossypiboma is more serious than treating it. The purpose of introducing this case is to express the importance of this fact that Gossypiboma should be considered in patients who referred for surgery after unexplained symptoms. It is suggested that the reasons for forgetting the medical staff in the occurrence of these medical malpractices be considered. Due to the fact that medical malpractice can undermine people's trust in the health system, classes on increasing concentration and forgetfulness treatment should be held in the health staff.

Abbreviations:

CT: Computed tomography
IVP: Intravenous pyelography

Availability of data and material

Availability of data and materials Records and data pertaining to this case are in the patient's secure medical records in the zabol (IRAN) Amir-al-momenin Hospital.

Acknowledgements

Many thanks and appreciation for the sincere cooperation of the operating room staff of Amir Al-Momenin Hospital in Zabol, Iran. This article was published with the code A-10-3097-1 in the journal of Fasa University of Medical Sciences.

Conflict of Interests

The authors declare that they have no competing interests.

References

- 1.Kinker SP, Kinker A, Kinker M. Rare case of Gossypiboma as antiboma [Sterile chronic abscess] after twelve year of vaginal hysterectomy and laparoscopy approach. Southeast Asian Journal of Health Professional. 2022;4(1):19-21.
- 2.Fekadu G, Tolera A, Beyene Bayissa B, Merga BT, Edessa D, Lamessa A. Epidemiology and causes of intestinal obstruction in Ethiopia: A systematic review. SAGE Open Medicine. 2022;10:20503121221083207.

- 3.Kabba MS, Forde MY, Beckley KS, Johnny B, Jah-Kabba AM, Seisay SB, Dawoh AM, Ogundiran T. Gossypiboma with perforation of the umbilicus mimicking a complicated urachal cyst: a case report. BMC surgery. 2020;20(1):1-5.
- 4.Özsoy Z, Okan I, Daldal E, Dasiran MF, Angın YS, Şahin M. Laparoscopic removal of Gossypiboma . Case Reports in Surgery. 2015.
- 5.Zhou Y, Chen P, Qiao T, Chen YF, Zong L. Complete transmural migration of a retained surgical sponge: an atypical case in image mimicking intussusception: A case report. Medicine. 2017;96(42):1234-1.
- 6.Silva SM, Sousa JB. Gossypiboma after abdominal surgery is a challenging clinical problem and a serious medicolegal issue. ABCD. Arquivos Brasileiros de Cirurgia Digestiva (São Paulo). 2013;26:140-3.
- 7.Lata I, Kapoor D, Sahu S. Gossypiboma, a rare cause of acute abdomen: A case report and review of literature. International Journal of Critical Illness and Injury Science. 2011;1(2):157.
- 8.Verma A, Tran Z, Hadaya J, Williamson CG, Rahimtoola R, Benharash P. Factors Associated With Retained Foreign Bodies Following Major Operations. The American Surgeon. 2021;87(10):1575-9.
- 9.Wan W, Le T, Riskin L, Macario A. Improving safety in the operating room: a systematic literature review of retained surgical sponges. Current Opinion in Anesthesiology. 2009;22(2):207-14.
- 10.Amiian A. Gossypiboma : a case report. Cases Journal. 2008;1(1):1-3.
- 11.de Sousa JB, Martins BA, Ferreira IA, e Silva SM, de Oliveira PG. Transmural Migration of Gossypiboma with Intraluminal Small-Bowel Obstruction: A Case Report. The American Journal of Case Reports. 2020;21:e924506-1.
- 12.Utoo BT, Igbudu JT, Eke B. Retained post-operative foreign body of gynaecologic origin at ascending colon. Gynecol Obstet Case Rep. 2016;2:2.
- 13.Mahran MA, Toeima E, Morris EP. The recurring problem of retained swabs and instruments. Best Practice & Research Clinical Obstetrics & Gynaecology. 2013;27(4):489-95.
- 14.Vagholkar K, Kharde K. Gossypiboma : A diagnostic challenge but a surgeon's nightmare. Indian J App Res. 2014;4:472-3.
- 15.Stawicki SP, Evans DC, Cipolla J, Seamon MJ, Lukaszczuk JJ, Prosciak MP, Torigian DA, Doraiswamy VA, Yazzie NP, Gunter Jr OL, Steinberg SM. Retained surgical foreign bodies: a comprehensive review of risks and preventive strategies. Scandinavian Journal of Surgery. 2009;98(1):8-17.
- 16.Gebreselassie KH, Mummed FO, Gebrehiwot FG, Adam MB, Adam RY, Issack FH. Vesical Gossypiboma with Urethral Migration Causing Acute Urinary Retention: A Case Report and Literature Review.



17. Shaban Y, Elkbuli A, Ovakimyan V, Wobing R, Boneva D, McKenney M, Hai S. Rectal foreign body causing perforation: Case report and literature review. *Annals of Medicine and Surgery*. 2019;47:66-9.
18. Cruz Jr RJ, de Figueiredo LF, Guerra L. Intracolonic obstruction induced by a retained surgical sponge after trauma laparotomy. *Journal of Trauma and Acute Care Surgery*. 2003;55(5):989-91.
19. Gibbs VC, Coakley FD, Reines HD. Preventable errors in the operating room: retained foreign bodies after surgery-Part I. Current problems in surgery. 2007;44(5):281-337.
20. Kanat BH, Kutluer N, Bozan MB, Aksoy N, Öztürk T. Um EstadO Esquecido: Gossypiboma. ABCD. *Arquivos Brasileiros de Cirurgia Digestiva (São Paulo)*. 2021 :14;34.
21. Noei Teymoordash S, Arab M, Talayeh M, Raoufi M, Ghavami B, Nouri B. Asymptomatic Intra-abdominal Gossypiboma Mimicking Recurrent Ovarian Tumor. *Journal of Obstetrics, Gynecology and Cancer Research (JOGCR)*. 2021;6(2):99-104.
22. Dakubo J, Clegg-Lamptey JN, Hodasi WM, Obaka HE, Toboh H, Asempa W. An intra-abdominal Gossypiboma . *Ghana Medical Journal*. 2009;43(1):43.
23. Abdul-Karim FW, Benevenia J, Pathria MN, Makley JT. Case report 736: Retained surgical sponge (Gossypiboma) . with a foreign body reaction and remote and organizing hematoma. *Skeletal radiology*. 1992;21(7):466-9.
24. Kato K, Suzuki K, Sai S, Murase T, Haruta J. A case of paravesical foreign body granuloma due to surgical sponge retained for 40 years. *Hinyokika kiyo. Acta Urologica Japonica*. 2000;46(7):491-4.
25. Alabi KO, Fayose SB, Akinwumi AI, Adeyeye A. Gossypiboma : A case report. *J Clin Images Med Case Rep*. 2021;2(5):1359.
26. Celik H, Akin IB, Altay C, Bisgin T, Obuz F. Giant Gossypiboma presenting as a pelvic mass. *Radiology Case Reports*. 2021;16(11):3308-10.
27. Bozkırlı BO, Gündoğdu RH, Ersoy PE, Akbaba S, Oduncu M. Gossypiboma mistaken for a hydatid cyst: case report. *Turkish Journal of Surgery*. 2020;36(4):405.
28. Herr KD. Scientific and Educational Abstracts Presented at The 30th Anniversary ASER 2018 Annual Scientific Meeting and Postgraduate Course in Emergency and Trauma Radiology September 26-29, McLean, Virginia. *Emergency Radiology*. 2018;25:565-611.
29. Kiernan F, Joyce M, Byrnes CK, O'Grady H, Keane FB, Neary P. Gossypiboma : a case report and review of the literature. *Irish journal of medical science*. 2008;177(4):389-91.
30. Saxena N, Kardam DK, Chauhan R, Chaudhary T. Gossypiboma -Successful retrieval through laparoscopy: A case report. *International Journal of Surgery Case Reports*. 2021; 84:106109.