



Original Article

## Effects of N-Acetylcysteine on FAS Gene Expression Level in Testicular Tissue of Acrylamide-Treated Adult Rats

Shahrzad E<sup>1,2</sup>, Shariati M<sup>3\*</sup>, Naeimi S<sup>4</sup>, Edalatmanesh MA<sup>2</sup>

1. Department of Biology, Fars Science and Research Branch, Islamic Azad University, Fars, Iran

2. Department of Biology, Shiraz Branch, Islamic Azad University, Shiraz, Iran

3. Department of Biology, Kazerun Branch, Islamic Azad University, Kazerun, Iran

4. Department of Genetics, Kazerun Branch, Islamic Azad University, Kazerun, Iran

Received: 10 Mar 2021 Accepted: 21 Jun 2021

### Abstract

**Background & Objectives:** Acrylamide (ACR) is a chemical with toxic effects on various body tissues. The present study was conducted to investigate the antioxidant effect of N-acetylcysteine (NAC) on the level of testicular apoptosis in acrylamide-treated adult rats.

**Material & Methods:** Thirty-six adult male Wistar rats were randomly divided into 6 equal groups. The intact control group was without treatment, the positive control group (PC) received 50 mg/kg ACR by oral gavage, the negative control group (NC) received 40 mg/kg NAC intraperitoneally, the animals in experimental groups of 1 (EXP1), 2 (EXP2) and 3 (EXP3) received 10, 20 and 40 mg/kg NAC intraperitoneally, respectively, and then all groups received 50 mg/kg acrylamide by oral gavage. The treatment period in all groups was 28 days. At the end of the study, FAS mRNA expression level was measured by real-time PCR and testicular tissue was evaluated histopathologically.

**Results:** The PC group showed a significant increase in FAS gene expression level ( $p < 0.05$ ) and spermatogenic degradation compared to the intact control and NC groups. The EXP1 and EXP2 groups showed decrease in FAS gene expression level ( $p < 0.05$ ) and spermatogenesis improvement in a dose-dependent manner while the EXP3 group exhibited a significant decrease in FAS gene expression level ( $p < 0.05$ ) and complete spermatogenesis recovery compared to the PC group.

**Conclusion:** The findings indicate that ACR increases apoptosis and destroys spermatogenesis by increasing FAS gene expression levels. In contrast, at the maximum dose (40 mg/kg), NAC could inhibit ACR-induced apoptosis by reducing FAS gene expression and improves spermatogenesis in rats.

**Keywords:** Apoptosis, N-acetylcysteine, Acrylamide, Testis, Rat

### Introduction

Acrylamide (ACR) is a carcinogenic mutagen chemical that is produced by cooking starch at high temperatures (120° C). At this temperature, ACR is produced by Millard reaction between reducing sugars and amino acids. In addition,

it has wide applications in various industries and laboratories such as dye synthesis, water treatment, cosmetics and gel electrophoresis (1-4). Skeletal muscle weakness, ataxia, and weight loss have been reported in humans and animals with long-term exposure to ACR (5). Thus, it appears that ACR is a potential hazard to human and animal health (6). ACR is rapidly absorbed in the body and oxidizes to Glycidamide (GA) by CYP2E1. GA can be

**\*Corresponding Author: Shariati Mehrdad,**

Department of Biology, Kazerun Branch, Islamic Azad University, Kazerun, Iran

Email: mehrdadshariati@kau.ac.ir

<https://orcid.org/0000-0001-7360-0208>



detoxified by combining with glutathione as well as by hydrolysis in the body. It can also react with DNA as well as protein (with the SH group) via the Michael reaction. GA-guanine adducts have been identified in mice and rats, which may be associated with mutations in somatic and germ cells (1, 7). ACR and its metabolites can induce oxidative stress in various tissues of the body, including the reproductive system, by reducing glutathione and increasing peroxidation of lipids as well as altering the expression of apoptosis-related proteins such as Bax, Bcl2 and Caspase3 (7-10). Spermatogenesis is a complex and dynamic process associated with the proliferation and apoptosis of germ cells. Germ cell apoptosis is essential to maintain germ cell population and appears to occur in Sertoli cells via the paracrine apoptotic pathway called FAS/FASL. FAS is a type I transmembrane protein that belongs to the family of tumor necrosis factor receptor (TNF) and neuronal growth factor and induces apoptosis. FASL is expressed by Sertoli cells and binds to its receptor (FAS) expressed by germ cells and controls the germ cell population by this mechanism. Increased oxidative stress can be associated with increased apoptosis in germ cells and other cells of the reproductive system (11).

Previous studies have indicated that using antioxidant compounds can modulate the harmful effects of ACR on various body tissues such as brain, liver, lung, kidney and testes. Antioxidants protect the body cells against harmful oxidative reactions by scavenging free radicals and reducing oxidative stress (12). NAC is a thiol group-containing antioxidant used extensively as a precursor for glutathione and antidote for acetaminophen poisoning. The antioxidant mechanism of NAC is mediated by maintaining the equilibrium of redox system in cells and by increasing intracellular glutathione levels and scavenging free radicals (13). NAC prevents apoptosis in various tissues and is used in the treatment of various disorders related to oxidative stress such as chronic bronchitis and ulcerative colitis. It is also used to control the symptoms of diseases such as Parkinson's,

Alzheimer's, HIV infection, asthma, cancer, and heart diseases (12, 14). The studies show that long-term use of NAC is secure even at high doses and does not adversely affect maternal and fetal health during pregnancy (14, 15). Given the beneficial and therapeutic effects of NAC, it seems that it is able to modulate the negative effects of ACR on various body tissues. Since ACR plays an important role in inducing oxidative stress and apoptosis in various tissues of the body including the reproductive system (7, 10), Hence, it is necessary to study the compounds that may inhibit the toxic effects of ACR. Therefore, this study was designed to investigate the effect of NAC as an antioxidant on FAS gene expression as a marker of apoptosis and histopathological changes of testicular tissue in ACR-treated adult rats.

## Materials & methods

### Animals

In this experimental study, 36 adult male Wistar rats weighing  $220 \pm 20$  g were provided from the animals' house at Islamic Azad University of Kazerun and were kept at standard conditions at  $22 \pm 2$  °C, 12 hours of darkness/daylight and 70% humidity in triplicate in polycarbonate cages. Before starting the study, the animals were kept for 2 weeks in the above-mentioned standard conditions to adapt to the new environmental conditions. During the study, the animals had adequate and free access to pelleted food and water ad libitum. The protocol of this study was approved by the Ethics Committee of Islamic Azad University of Kazerun, Iran, in relation to working with laboratory animal care.

### Experimental protocol

Animals were randomly divided into 6 equal ( $n=6$ ) control, positive control (PC), negative control (NC), experimental 1 (EXP1), experimental 2 (EXP2) and experimental 3 (EXP3) groups. The control group received no treatment. Animals in the PC group received 50 mg/kg ACR (Merck, Germany) by oral gavage at 5 pm every day. Animals in the NC group

received 40 mg/kg NAC (Merck, Germany) intraperitoneally at 9 am every day. EXP1, EXP2 and EXP3 groups received 10, 20 and 40 mg/kg NAC intraperitoneally, respectively, every day at 9 am and then received 50mg/kg ACR at 5 pm by oral gavage. The experimental period was the same in all groups and it was for 28 days. The administrated doses of NAC and ACR were determined based on the previous studies (7, 16). At the end of the study, the animals were anesthetized with ether (Merck, Germany), and the abdominal cavity was opened and the left and right testes of all rats were removed for histopathological examination and studying FAS expression level.

### Histopathological analysis of testicular tissue

The left and right testes of all animals were removed from the abdominal cavity and blocked in 10% formalin buffer solution and were molded in paraffin using the conventional histological procedures, then some transverse cuttings of 5-microns were provided from each testis and were stained with hematoxylin-eosin. Under a light microscope (Nikon, Tokyo, Japan) and using a 40X Lattice lens, the number of spermatogonia, spermatocyte and spermatid cells were counted randomly in each sectioning in five different areas in the wall of seminiferous tubules randomly. Sertoli and Leydig cells were then counted with the magnification of 40X.

To count sperm, testes epididymis was removed and placed in normal saline and after fragmentation, the sperms were counted using a 10X neobar lam. For this purpose, the samples were diluted 40 times with 0.5% formaldehyde and the sperms were counted in four large squares and multiplied by 500,000.

### Quantitative analysis of FAS gene expression using real-time PCR

The removed samples were washed twice with saline phosphate buffer and then a small piece of testicular tissue was floated in the liquid nitrogen for 1 to 2 minutes to extract RNA and after complete evaporation, it was powdered using mortar. One cc Trisol was added and

homogenized alternately with a micro-tube with a manual homogenizer on ice for two minutes. After homogenization, the sample was kept at room temperature for 5 minutes and then 200  $\lambda$  chloroform was added for dehydration. The sample was shaken vigorously for 15 seconds to turn milky. The milky sample was centrifuged for 15 min at 4 ° C using a refrigerated centrifuge at 12000 RCF. Then the RNA-containing supernatant was separated using a sterile micro-tube.

A volume of RB1 buffer was added to the supernatant-containing micro-tube. The micro-tube contents were then transferred to the column. After 30 seconds centrifuge at room temperature at 12000 RCF, the media below the column was removed and 500  $\mu$ L of SW1 buffer was added. After 30 seconds centrifuge at room temperature and 12000 RCF, the media below the column was again removed. In the next stage, 500  $\mu$ L of RNW buffer was added to the column and after centrifugation at room temperature and 12000 RCF, the columns were transferred to a new micro-tube and 50  $\mu$ L nuclease-free water was added and purified after centrifugation in 12000 RCF RNA.

In order to quantitatively evaluate the RNA concentration, two  $\lambda$  from the original sample were isolated before inserting on a thermo cycler and the concentration and efficiency of RNA were measured using a NanoDrop spectrophotometer. The mRNA was converted to complementary DNA (cDNA) by reverse transcription reaction. After reverse transcription reaction, cDNA was made to amplify the target fragment and quantitatively evaluate gene expression.

RT-PCR reaction was conducted using FAS-specific primer (Table 1) and Power SYBR green PCR master mix (Applied Biosystems, UK) reaction mixture and Real-time PCR system step one plus (Applied Biosystems, UK) at a temperature of 95 ° C for 10 minutes, 40 cycles of denaturation at 95 ° C for 15 second, annealing at 95 ° C for 30 second and amplification at 72 ° C for 40 seconds. To evaluate the work done at this stage,  $\beta$ -Actin gene was examined as



the housekeeping gene. The mean of CTs was calculated using  $2^{-\Delta CT}$ . The sequence of primers used in this study is given in Table 2.

### Statistical analysis

Using SPSS software version 20 (SPSS Inc., Chicago, IL), the normal distribution of data was confirmed by Kolmogorov-Smirnov test and then using one-way ANOVA and LSD test, the significance of data between the control group and the treated groups was evaluated at  $P=0.05$ . The results were expressed as mean  $\pm$  standard deviation in the graph (GraphPad Prism 6, Inc., San Diego, CA, USA) and the table.

## Results

### FAS gene expression findings

The measurement of FAS gene expression level using RT-PCR showed (Chart 1) that in the PC group (50 mg/kg ACR), the level of FAS gene expression has significantly increased compared to the intact control group ( $P=0.05$ ). In the NC group (40 mg/kg NAC), the level of FAS gene expression was not significantly different from the intact control group ( $P=0.05$ ). In EXP1 (50 mg/kg ACR + 10 mg/kg NAC) and EXP2 (50 mg/kg ACR + 20 mg/kg NAC) groups, FAS gene expression level indicated a dose-dependent manner decrease but it was not significant ( $P=0.05$ ). The EXP3 group (50 mg/kg ACR + 40 mg/kg NAC) showed a significant decrease in FAS gene expression level compared to the intact control group ( $P=0.05$ ).

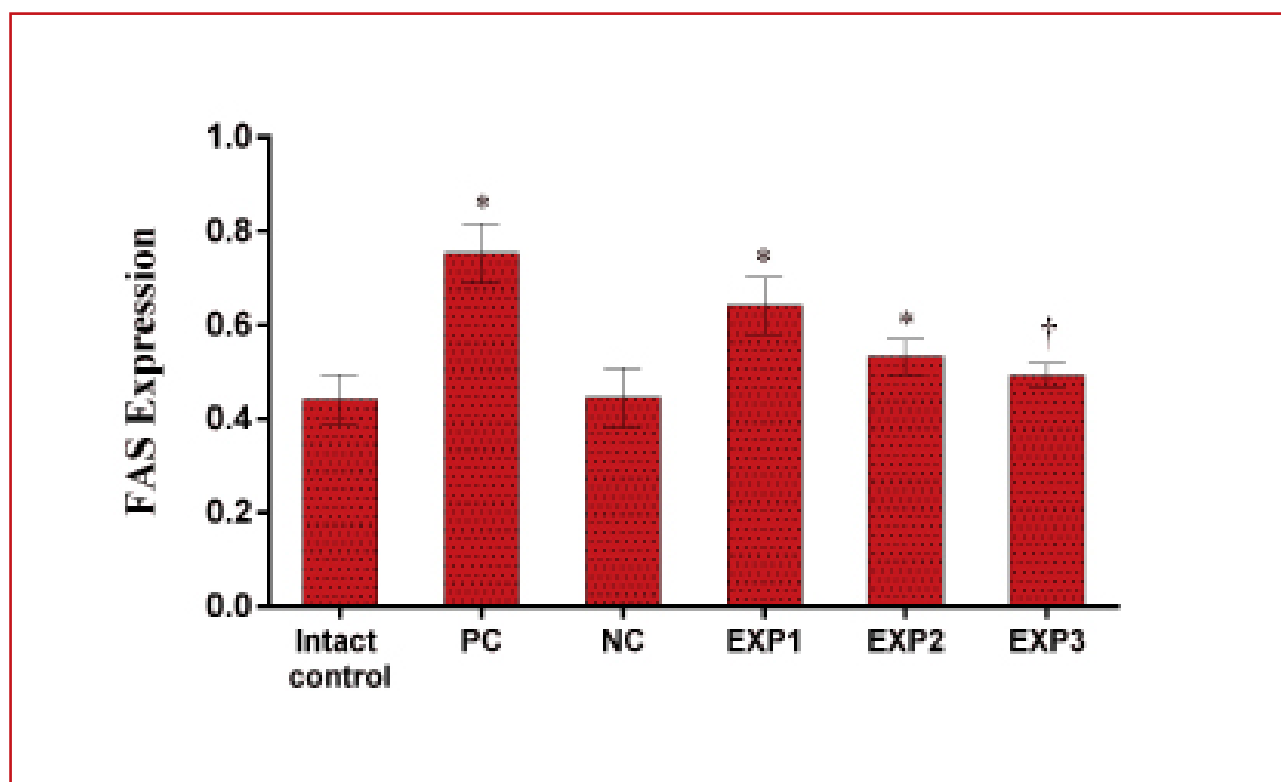
### Histopathologic findings

Table 2 represents the effect of ACR and NAC on the number of spermatogenic, Sertoli and Leydig cells in different groups. In the PC group, the number of spermatogonia, spermatocyte, spermatid, sperm and Leydig cells significantly decreased ( $P=0.05$ ). The NC group showed no significant difference in the number of spermatogonia, spermatocyte, spermatid, sperm and Leydig cells compared

to the intact control group ( $P=0.05$ ), but there was a significant increase in the PC group ( $P=0.05$ ). The EXP1 group showed a significant decrease in the number of spermatogonia, spermatocyte, spermatid, sperm and Leydig cells compared to the intact control group ( $P=0.05$ ), but only the number of spermatogonia and spermatocyte showed a significant increase compared to the PC group ( $P=0.05$ ). The number of spermatogonia and spermatocytes in the EXP2 group showed a significant decrease ( $P=0.05$ ) and increase ( $P=0.05$ ) compared to the intact control and PC groups, respectively, while the number of spermatids, sperm and Leydig cells in this group did not have a significant difference compared to the intact control group ( $P=0.05$ ), but there was a significant increase compared to the PC group ( $P=0.05$ ). The EXP3 group showed a significant increase in the number of spermatogonia, spermatocyte, spermatid, sperm and Leydig cells compared to the PC group ( $P=0.05$ ), while there was no significant difference compared to the intact control group ( $P=0.05$ ). There was no significant difference in the number of Sertoli cells in all the groups compared to the intact control group ( $P=0.05$ ).

According to the histological findings (Figure 1), normal spermatogenesis in the intact control group was complete and all spermatogenic cell types and Sertoli cells were observed in seminiferous tubes (Figure 1A and 1B). In the PC group, reduced thickness of the germinal epithelium, the presence of vacuoles and apoptotic bodies were observed in seminiferous tubes (Figure 1C and 1D). In the NC group, spermatogenesis was similar to that in the control group (Figure 1E and 1F). In the EXP1 group, spermatogenesis showed partial improvement despite vacuolar spaces in the germinal epithelium (Figure 1G and 1H). In the EXP2 (Figure 1I and 1J) and EXP3 (Figure 1K and 1L) groups spermatogenesis was more similar to the intact control group in seminiferous tubes and normal spermatogenesis was observed.

**Chart 1.** The comparison of mean and standard deviation of FAS gene expression levels in different groups.



\*Compared to the intact control group

† Compared to the PC group

**Table 1.** RT-PCR sequencing primers of  $\beta$ -Actin and FAS genes as housekeeping and apoptosis markers, respectively in this study.

Gene name-Direction	Primer sequence (5'-3')
$\beta$ -Actin-Forward	CGTGCGTGACATTAAAGAGAA
$\beta$ -Actin-Reverse	CGCTCATTGCCGATAGTGAT
FAS-Forward	GCAATGCTTCTCTCTGTGACCACT
FAS-Reverse	GCTGTTGTGCTCGATCTCATCG

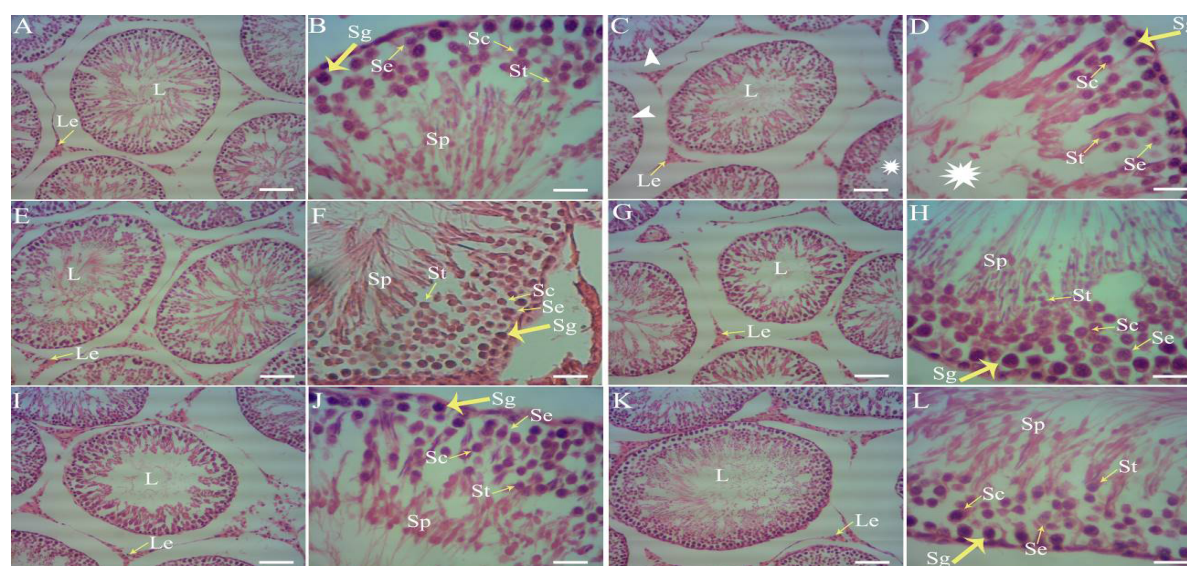


**Table 2.** The comparison of mean and standard deviation of spermatogonia, spermatocyte, spermatid, sperm, Leydig and Sertoli cell numbers in different groups.

Groups	Spermatogonia	Spermatocyte	Spermatid	Sperm	Sertoli	Leydig
Intact control	69.50±4.50	66.16±3.48	61.66±9.83	65±20.24	22±2.82	6.83±0.98
PC	36.66±10.03*	34.33±11.16*	41.66±6.05*	45.83±3.76*	20.33±1.36	4±1.67*
NC	62.83±12.81†	58.33±11.91†	59.16±7.35†	62.50±14.05†	21.33±1.96	6.50±1.04†
EXP1	50.83±10.36*†	45±13.59*†	45.83±8.01*	48.33±4.08*	20.50±1.87	4.16±1.47*
EXP2	56.66±9.33*†	52.33±2.25*†	55±4.47†	61.66±4.08†	20.83±1.16	5.83±1.72†
EXP3	62.16±2.99†	56±7.15†	55.83±5.84†	63.33±4.08†	21±1.89	6.33±1.21†

\*Compared to the intact control group

† Compared to the PC group



**Figure 1.** The photomicrograph of testicular tissue in rats treated with ACR and NAC in different groups.

Normal spermatogenesis is observed in the control group (A and B). In the PC group, decreases sperm density, presence of vacuoles (white arrowheads) and extensive lumen (white stars) are observed in germinal epithelium. Spermatogenesis has destroyed (C and D). The NC group showed normal spermatogenesis (E and F). The EXP1 group showed only a small

amount of spermatogenic cells, although a slight improvement in spermatogenesis was observed (G and H). The EXP2 (I and J) and EXP3 (K and L) groups showed complete spermatogenic cell lines and improved spermatogenesis. L: Lumen; Le: Leydig; Sg: Spermatogonia; Sc: Spermatocyte; St: Soermatid; Sp: Sperm; Se: Sertoli. H&E staining. White bars, 100 μm.



## Discussion

In the present study, the effect of ACR and NAC on FAS gene expression level, spermatogenic, Sertoli and Leydig cell numbers in adult rats for 28 days was investigated. The gene expression results in this study indicate that following the administration of ACR at a dose of 50 mg/kg, the expression level of the FAS gene in the testis of adult rats has increased. This result is consistent with the findings of the previous studies (7). It has been reported that following ACR administration, glutathione levels decrease and subsequently lipid peroxidation increases (17). Decreased glutathione levels and altered redox state of cells may result in changes in gene expression and consequently apoptosis (18). Apoptosis or programmed cell death is a selective process where the balance between proliferation and cell death is regulated and induced by DNA damage or oxidative stress (19). In ACR-treated rats, ACR residues have been found in the testis, epididymis, seminal vesicle, and prostate and this indicates that ACR could pass through the blood-epididymis and blood-testis barriers and damages the male reproduction system (20). The findings indicate that ACR can induce the caspase-3-dependent apoptosis pathway by increasing oxidative stress, which is involved in the cleavage of the cell nucleus in the late stages of apoptosis in the rat testis. The death receptor activation pathway consists of a FAS signaling complex and procaspase-8 that activate caspase-8. Caspase-8 can directly activate caspase-3 and thus induces apoptosis (19).

According to our results, administration of ACR at a dose of 50 mg/kg reduces the number of spermatogonia, spermatocyte, spermatid and Leydig cells, but does not influence the number of Sertoli cells. The relationship between ACR and increased oxidative stress in testicular tissue has been shown in some studies (7, 12). ACR can inhibit the activity of cytoskeletal motor proteins such as Dynein and Kinesin. Motor proteins play a key role in integrating cytoskeletal elements such as microfilaments, microtubules and intermediate filaments into functional units.

The degradation of the cytoskeleton by ACR can influence cell-cell adhesion, cell shape, intracellular communication, metabolism, synthesis and bio-chemicals secretion, so this could be an explanation that ACR can damage the reproductive system by targeting the cytoskeletal system. (7). Destroying the cytoskeleton by ACR decreases cholesterol uptake by Leydig cells resulting in reduced testosterone synthesis. In addition, the destruction of the cytoskeleton may be accompanied by the control or the transfer of LH membrane receptors in Leydig cells, which indirectly decreases testosterone levels (21, 22). Decreased testosterone causes histopathologic changes, such as increased apoptotic cells, decay and decreased spermatogenic cells, and the decreased survival of Leydig cells. Also, the degradation of the cytoskeleton can weaken or destroy tight junctions between Sertoli cells and germ cells, thereby destroying spermatogenesis (23). On the other hand, ACR can increase the level of malondialdehyde as an indicator of lipid peroxidation and the level of myeloperoxidase as an endogenous lysosomal enzyme in testicular tissue, thereby inducing oxidative stress-dependent apoptosis in spermatogenic and Leydig cells. (6).

In this study, the administration of different doses of NAC in ACR-treated rats was associated with a decrease in FAS gene expression level, whereas at a maximum dose we observed a significant decrease in FAS gene expression level. It has been shown that the administration of NAC has not increased the FAS gene expression levels in H9c2 cells (24). In our study, the administration of NAC in the NC group did not change the level of FAS gene expression compared to the control group, which is consistent with the previous studies. NAC, as an antioxidant and modulator of intracellular redox reactions can exert its effects in three ways: 1- indirectly acts as glutathione precursor and causes the synthesis of this antioxidant; 2- reacts directly with free radicals and eliminates them; 3- regulating intracellular redox reactions by disulfide breakdown and restoring Thiol content (12, 25). The evidence suggests that



NAC plays a role in down-regulating FAS gene expression. NAC reduces the sensitivity of these cells to FAS-mediated apoptosis by affecting Jurkat and T cells. It appears that NAC is able to modulate the activity of the enzyme responsible for FAS cleavage (26). Malondialdehyde is a mutagenic product of lipid peroxidation that is increased by ACR treatment. The administration of NAC (150 mg/kg) in ACR-treated rats (40 mg/kg) can decrease the levels of malondialdehyde and myeloperoxidase in rat testis and increase glutathione levels (12). It has also been shown that the administration of NAC in a torsional testis decreases Malondialdehyde levels and increases glutathione peroxidase levels. Therefore, it seems that NAC can counteract the negative biochemical changes associated with oxidative stress (27).

In the present study, the administration of different doses of NAC in ACR-treated rats improved the number of spermatogonia, spermatocyte, spermatid and leydig cells compared to the PC group. During spermatogenesis, many germ cells die before they reach maturity during the normal process of apoptosis. Increased oxidative stress followed by increased free radicals such as reactive oxygen species can increase apoptosis while damaging germ cells. In vitro studies suggest that NAC reduces the levels of reactive oxygen species in human semen and improves semen parameters such as the count, motility, morphology and fragmentation of sperm DNA (28, 29). Other studies have also shown that in mice treated with Paranonylphenol, NAC administration can improve testosterone levels and spermatogenic indexes compared to the control group (30). It has also been shown that in rats treated with Titanium Dioxide, spermatogonial and spermatocytes are more sensitive to apoptosis factors than Sertoli and Leydig cells, whereas NAC administration can reduce apoptosis in these cells and other spermatogenic cells (31). The limitations of the present study include the short duration of treatment, the lack of administering higher doses of NAC and not studying other genes associated with apoptosis such as Caspases and Bcl-2. Therefore, to obtain better

results, a longer duration of treatment and administration of higher doses of NAC should be selected in future studies. In addition, different genes associated with apoptosis should be evaluated.

# Conclusion

The results of this study indicate that ACR can increase apoptosis in testicular tissue of rats by increasing the expression level of FAS gene and disrupts spermatogenesis during 28 days. In contrast, at the maximum dose (40 mg/kg), NAC administration in ACR-treated male rats can decrease FAS gene expression and improve spermatogenesis.

# Acknowledgement

The authors would like to thank the Islamic Azad University of Kazerun and the Islamic Azad University of Shiraz for their cooperation in this study. (Ethical code No: IR.IAU.SHIRAZ.16330525951004).

# Conflict of Interest

The authors have no conflict of interest to declare.

# References

- 1.Klaunig JE. Acrylamide carcinogenicity. *J Agric Food Chem.* 2008; 56:5984-5988.
- 2.Liu Z, Song G, Zou C, Liu G, Wu W, Yuan T, et al. Acrylamide induces mitochondrial dysfunction and apoptosis in BV-2 microglial cells. *Free Radic Biol Med.* 2015; 84:42-53.
- 3.Ma Y, Shi J, Zheng M, Liu J, Tian S, He X, et al. Toxicological effects of acrylamide on the reproductive system of weaning male rats. *Toxicol Ind Health.* 2011;27:617-627.
- 4.Parzefall W. Minireview on the toxicity of dietary acrylamide. *Food Chem Toxicol.* 2008;46:1360-1364.
- 5.Zamani E, Shokrzadeh M, Fallah M, Shaki F. A review of acrylamide toxicity and its mechanism. *Pharm Biomed Res* 2017; 3:1-7.
- 6.Alturfan Ek, Beceren A, Şehirli AO, Demiralp ZE, Şener G, Omurtag GZ. Protective effect of N-acetyl-L-cysteine against acrylamide-induced oxidative stress in rats. *Turk J Vet Anim Sci.* 2012; 36:438-445.
- 7.Camacho L, Latendresse JR, Muskhelishvili L, Patton R, Bowyer JF, Thomas M, et al. Effects of acrylamide exposure on serum hormones, gene expression, cell proliferation, and histopathology in male reproductive tissues of Fischer 344 rats. *Toxicol Lett.* 2012;211: 135-143.
- 8.Mehri S, Abnous K, Khooei A, Mousavi SH, Shariaty





- VM, Hosseinzadeh H. Crocin reduced acrylamide-induced neurotoxicity in Wistar rat through inhibition of oxidative stress. *Iran J Basic Med Sci.* 2015; 18:902-908.
9. Li SX, Cui N, Zhang CL, Zhao XL, Yu SF, Xie KQ. Effect of subchronic exposure to acrylamide induced on the expression of bcl-2, bax and caspase-3 in the rat nervous system. *Toxicology.* 2006; 217:46-53.
10. Pan X, Wu X, Yan D, Peng C, Rao C, Yan H. Acrylamide-induced oxidative stress and inflammatory response are alleviated by N-acetylcysteine in PC12 cells: Involvement of the crosstalk between Nrf2 and NF- $\kappa$ B pathways regulated by MAPKs. *Toxicol Lett.* 2018;288:55-64.
11. Shukla KK1, Mahdi AA, Rajender S. Apoptosis, spermatogenesis and male infertility. *Front Biosci (Elite Ed).* 2012;4:746-754.
12. Alturfan EI, Beceren A, Şehirli AO, Demiralp ZE, Şener G, Omurtag GZ. Protective effect of N-acetyl-L-cysteine against acrylamide-induced oxidative stress in rats. *Turk J Vet Anim Sci.* 2012; 36:438-445.
13. Liu Y, Liu K, Wang N, Zhang H. N acetylcysteine induces apoptosis via the mitochondria dependent pathway but not via endoplasmic reticulum stress in H9c2 cells. *Mol Med Rep.* 2017; 16:6626-6633.
14. Mokhtari V, Afsharian P, Shahhoseini M, Kalantar SM, Moini A. A review on various uses of N-Acetylcysteine. *Cell J.* 2017; 19:11-17.
15. Demedts M, Behr J, Buhl R, Costabel U, Dekhuijzen R, Jansen HM, et al. High-dose acetylcysteine in idiopathic pulmonary fibrosis. *The New England Journal of Medicine.* 2005; 353:2229-2242.
16. Chiew AL, Isbister GK, Duffull SB, Buckley NA. Evidence for the changing regimens of acetylcysteine. *Br J Clin Pharmacol.* 2016; 8:471-481.
17. Yousef MI, El-Demerdash, FM. Acrylamide-induced oxidative stress and biochemical perturbations in rats. *Toxicology.* 2006; 219:133-141.
18. Schulze-Osthoff K, Los M, Baeuerle PA. Redox signaling by transcription factors NF-kappa B and AP-1 in lymphocytes. *Biochem Pharmacol.* 1995; 50:735-741.
19. Zhang X, Chen F, Huang Z. Apoptosis induced by acrylamide is suppressed in a 21.5% fat diet through caspase-3-independent pathway in mice testis. *Toxicol Mech Methods.* 2009; 19:219-224.
20. Ma Y, Shi J, Zheng M, Liu J, Tian S, He X, et al. Toxicological effects of acrylamide on the reproductive system of weaning male rats. *Toxicol Ind Health.* 2011;27:617-627.
21. Oshima, RG. Intermediate filaments: a historical perspective. *Exp Cell Res.* 2007;313: 1981-1994.
22. Rogers SL, Gelfand VI. Membrane trafficking, organelle transport, and the cytoskeleton. *Curr Opin Cell Biol.* 2000; 12:57-62.
23. Hasanin NA, Sayed NM, Ghoneim FM, Al-Sherief SA. Histological and ultrastructure study of the testes of acrylamide exposed adult male albino rat and evaluation of the possible protective effect of vitamin e intake. *J Microsc Ultrastruct.* 2018;6(1):23-34.
24. Liu Y, Liu K, Wang N, Zhang H. N acetylcysteine induces apoptosis via the mitochondria dependent pathway but not via endoplasmic reticulum stress in H9c2 cells. *Mol Med Rep.* 2017; 16:6626-6633.
25. Aldini G, Altomare A, Baron G, Vistoli G, Carini M, Borsani L, et al. N-Acetylcysteine as an antioxidant and disulphide breaking agent: the reasons why. *Free Radic Res.* 2018; 52:751-762.
26. Delneste Y, Jeannin P, Seville E, Aubry JP, Bonnefoy JY. Thiols prevent Fas (CD95)-mediated T cell apoptosis by down-regulating membrane Fas expression. *Eur J Immunol.* 1996; 26:2981-2988.
27. Cay A, Alver A, Küçük M, Işık O, Eminağaoğlu MS, Karahan SC, et al. The effects of N-acetylcysteine on antioxidant enzyme activities in experimental testicular torsion. *The Journal of Surgical Research.* 2006; 131:199-203.
28. Erkkilä K, Hirvonen V, Wuokko E, Parvinen M, Dunkel L. N-acetyl-L-cysteine inhibits apoptosis in human male germ cells in vitro. *J Clin Endocrinol Metab.* 1998; 83:2523-31.
29. Jannatifar R, Parivar K, Hayati Roodbari N, Nasr-Esfahani MH. Effects of N-acetyl-cysteine supplementation on sperm quality, chromatin integrity and level of oxidative stress in infertile men. *Reprod Biol Endocrinol.* 2019;17(1):24.
30. Malmir M, Faraji T, Noreini NS, Mehranjani SM. Protective antioxidant effects of n-acetylcysteine on testicular tissue and serum testosterone in paraneoplastic-treated mice (A Stereological Analysis). *Reprod Syst Sex Disord.* 2018; 7:1000225.
31. El-Kirdasy AF, Nassan MA, Baiomy AAA, Ismail TA, Soliman MM, Attia HF. Potential ameliorative role of n-acetylcysteine against testicular dysfunction induced by titanium dioxide in male albino rats. *Am J Pharmacol Toxicol.* 2014; 9:29-38.